Olea medical

Improved diagnosis for life™

Did You Know?

Ischemic Stroke Physiopathology

Take-home message

- The three most common types of stroke:
  - cerebral thrombosis
  - brain embolism
  - cerebral hemorrhage
- Acute stroke is increasingly recognized as a medical emergency
- MRI has a significantly higher sensitivity and specificity than CT in the diagnosis of acute ischemic infarction in the first hours after the onset of symptoms **(Ref 2)**

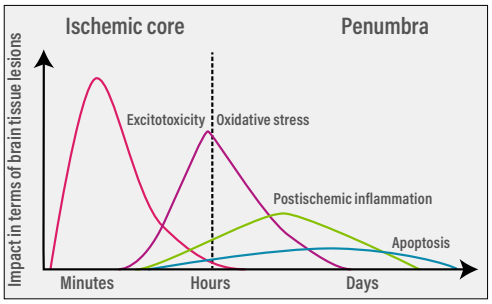

Spatio-temporal evolution of the mechanisms involved in cerebral ischemia (Correspondances in Vascular Neurology Vol VI, Jan 2006, Deplanque)

- **Stroke is defined as a sudden-onset neurological deficit caused by ischemia or hemorrhage in brain. Ischemic stroke** represents approximately 87% of all strokes, it is caused by the localized occlusion of a vessel leading to a cessation of oxygen and glucose supply to the brain, resulting in a collapse of metabolic processes in the affected territory.

Physiopathology of ischemic stroke: after the interruption of blood supply, following the occlusion or hypoperfusion of a cerebral vessel, **neuronal death** occurs in the space of **a few minutes** in **the center of the infarcted area.** At the periphery of the infarcted area, called the **ischemic penumbra,** the brain tissue is functionally altered but still viable, the blood supply being made by **collateral vessels.** This ischemic penumbra zone can be transformed into **infarcted tissue** following secondary neuronal lesions induced by a deleterious biochemical cascade leading to cytotoxic and excitotoxic effects (or **oxidative stress**) **(Ref 1).**

The cerebral lesion severity determined by occlusion of a cerebral artery depends on the duration of the occlusion and the possibilities of substitution from adjacent cerebral arteries.

Stroke risk factors

- Smoking
- Hypercholesterolemia
- Diabetes mellitus
- Hypertension
- Heart diseases

Possible treatment

- The administration of an intravenous recombinant tissue-type plasminogen activator (rt-PA)
- The deliverance of medication directly to the brain by means of a catheter through an artery in the groin
- Mechanical clots removal (thrombectomy): clot (thrombus) removal by means of a catheter
- To minimize the risk of stroke or TIA (Transient Ischemic Attack), it is possible to perform a procedure to open up an artery that's narrowed by fatty deposits (plaques): endarterectomy

In Olea Sphere®?

Modern magnetic resonance imaging (MRI) sequences, such as diffusion/perfusion weighted sequences, **help identifying the size of the infarcted area** and **the amount of tissue at risk**, even for small brainstem infarctions.

Arterial spin labeling (ASL) is an MRI method that enables the measurement of tissue perfusion without the use of exogenous contrast agents, by magnetically tagging the water in inflowing blood **(Ref 3) (Pic. 1 *).**

Intravoxel incoherent motion (IVIM) diffusion-weighted MRI can simultaneously measure diffusion and perfusion characteristics in a non-invasive way **(Ref. 4).** The IVIM-derived perfusion parameters for which the pseudo-diffusion coefficient D * and the vascular volume fraction were calculated with the bi-exponential model **(Pic. 2).**

Olea Nova Move™ allows to visualize dynamic contrast agent arrival to the brain tissue. This **"pseudo-angiography" effect** can be used to identify an occlusion of one of the main intracranial arteries **(Pic. 3),** as well as the **collateral circulation status.**

++

- **The presence of good collaterals is an independent predictive factor of early recanalization.**
  The status of collaterals is significant for the treatment decision.

◄ Picture 1

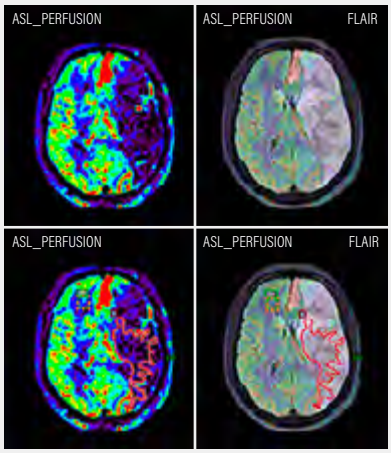

Series	1	2
ASL_PERFUSION_ WEIGHTER	3,96 [0,21]	18,6
MEAN_DIFFUSIVITY	0,35 [0,48]	0,74

Picture 2 ►

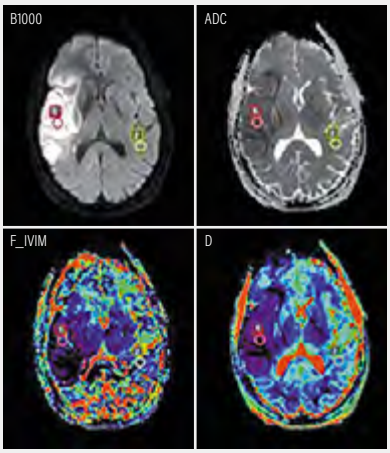

Series	1	2
B1000	321,2	132,95
ADC	0,41	0,68
F_IVIM	0,09	0,11
D	0,35	0,5

Picture 3 ►

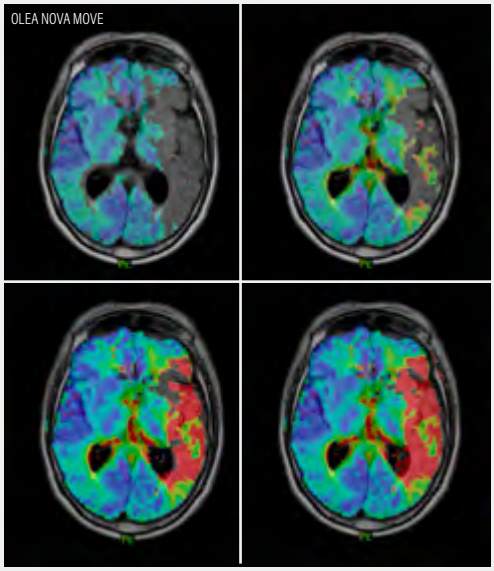

Sources: Ref ■ [1] European Stroke Initiative. Recommandations 2003 ■ Ref ■ [2] https://www.ncbi.nlm.nih.gov/pubmed/15628251 ■ Ref ■ [3] Detre JA, Leigh JS, Williams DS, Koretsky AP. Perfusion imaging. Magn Reson Med. 1992;23:37–45. ■ Ref [4] https://www.ncbi.nlm.nih.gov/pubmed/26748572 ■ http://acces.ens-lyon.fr/acces/thematiques/neurosciences/actualisation-des-connaissances/maladies-et-traitements/accidents-vasculaires-cerebraux-et-tumeurs/comprendre/causes-et-mecanismes-cellulaires/lexcitotoxicite-une-consequence-de-lischemie-cerebrale ■ https://www.pfizerpro.fr/condition/cardiovasculaire/laccident-vasculaire-cerebral/avc-physiopathologie-sous-jacente-complexe ■ http://www.medecine.ups-tlse.fr/DCEM2/MODULE%209/item%20133/133_poly_ACC_VASC_CEREB.pdf ■ http://www.ifsi-clermont60.fr/ifsi/coursbysad/docus/cours%20sur%20les%20AVC.pdf ■ https://www.infirmiers.com/etudiants-en-ifsi/cours/cours-neurologie-accident-vasculaire-cerebral.html - https://www.ncbi.nlm.nih.gov/pmc/articles/PMC3967005/ ■ V.A. // B.T. // A.M. // S.F. // R.P. // J.G.F.

*ASL, IVIM and Olea Nova Move ™ images show three different clinical cases. Olea Sphere® v3.0, medical imaging post-processing software, is a medical device manufactured and marketed by Olea Medical®. This medical device is reserved for health professionals. The software has been designed and manufactured according to the EN ISO 13485 quality management system. Read the instructions in the notice carefully before any use. Instructions for Use are available on http://www.olea-medical.com/en/ Manufacturer: Olea Medical® (France). Medical devices Class IIa / Notified body: CE 0459 LNE-GMED.