

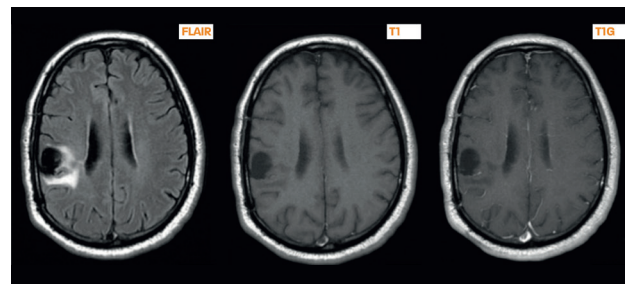
Brain Tumor: Low Grade & High Grade Gliomas



**Dr Christine Rodriguez-Régent
and Pr. Jean-François Meder,
Sainte-Anne Hospital Center - Paris - France**

Introduction

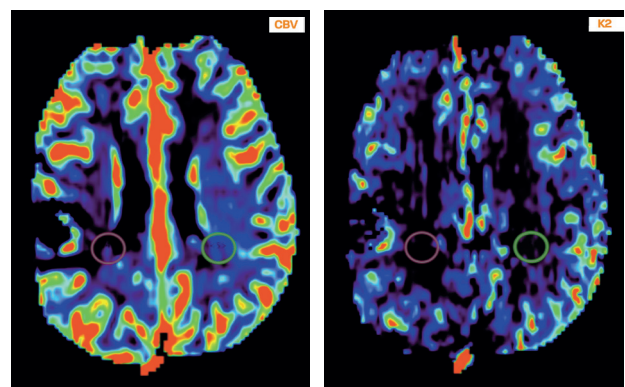
Gliomas are the most common primary cerebral neoplasms. The grading of gliomas is of utmost clinical importance as it determines the correct therapy. More aggressive treatment planning is required for the management of high grade tumors. The purpose of this case report is to illustrate the possible predictors, which might discriminate, between low and high grade gliomas using dynamic contrast-enhanced (DCE) perfusion in the follow-up of treated low grade gliomas.



Postoperative MRI (2009) - FLAIR, T1, T1 Gadolinium
No residual tumor. No enhancement in the postoperative cavity and in the adjacent white matter.

Case Report

A 54-year-old woman presented to the emergency room with a motor deficit of the left upper extremity. A brain MRI revealed a FLAIR hyperintense lesion in the right frontal lobe. The patient underwent a craniotomy with frameless stereotactic guidance for resection of the lesion. The histopathologic examination of the tumor was consistent with a low grade glioma.



No increase of the CBV or of the K2 in the postoperative cavity and in the adjacent white matter.

ROI (tumor) : 0.7
ROI (normal/reference): 1.41
Ratio : 0.5

ROI (tumor) : 1.92
ROI (normal)/reference: 4.32
Ratio : 0.4

Post-treatment and analysis

PWI images were processed with Olea Sphere® (Olea Medical®, La Ciotat, France) to display the CBV (Cerebral Blood Volume) and K2 (permeability) maps. Regions of interest (ROI) were identified and the corresponding perfusion graphs were assessed.

Diagnosis

The lesion was progressing from a low grade glioma to high-grade.

Treatment

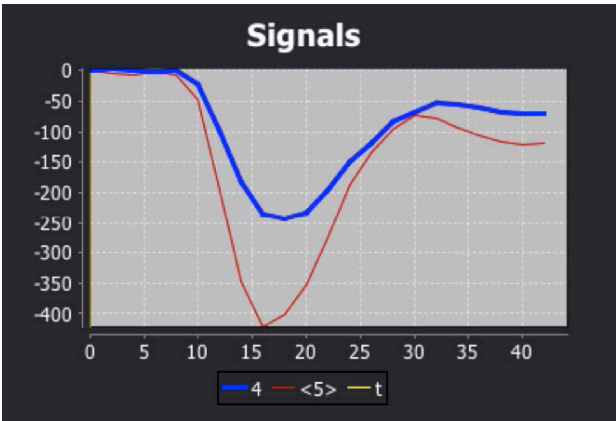
The patient has benefited from an early treatment with chemotherapy, and there is still today no malignant transformation.

Discussion

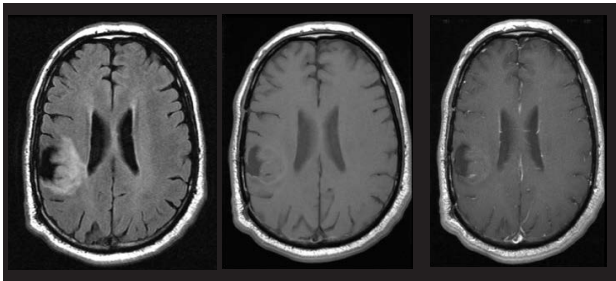
Neoangiogenesis is believed to be a key factor in the process of neoplastic transformation, which is essential for the rapidly growing tissue. CBV corresponds to the degree of vascularization and could discriminate tumor grade.

The property of migrating into neighboring cells and tissues is a key feature of gliomas, which increases, as it progresses from a low grade to high grade. K2 has been widely used to quantify the extent of BBB disruption and was found to differentiate low grade tumors and high grade tumors.

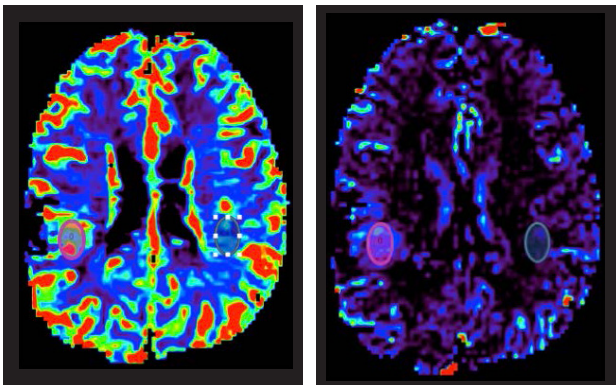
Increases in rCBV and K2 precede the development of contrast enhancement in transforming low grade gliomas; rCBV and K2 increases are therefore likely to provide an earlier noninvasive indicator of malignant progression. This has important implications for clinical management, by helping to identify patients most likely to benefit from early treatment. We therefore recommend that MR perfusion imaging be used routinely in the initial assessment and subsequent evaluation of patients with low grade gliomas.



Contrast agent concentration curves
Blue curve: ROI within the lesion
Red curve: reference ROI (normal tissue)
No increase of the CBV in the adjacent white matter of the postoperative cavity.

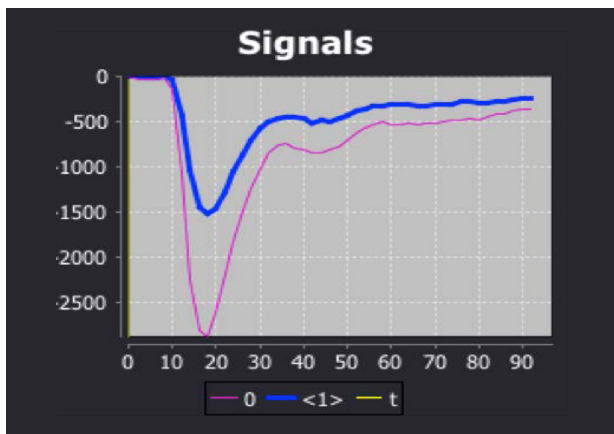


FOLLOW-UP : MR-perf (2010) - FLAIR, T1, T1 Gadolinium
Increase of the FLAIR hyperintense lesion.
No enhancement of the lesion after contrast injection.
In comparison with the postoperative MRI, there is no argument for a malignant transformation.



The increase of the CBV shows a high degree of neoangiogenesis and the increase of the K2 shows a good deal of disrupted blood-brain barrier. It has be proved that this results could predict a malignant transformation even before contrast enhancement.

ROI (tumor) : 2.27	ROI (tumor) : 45.33
ROI (normal/reference): 1.26	ROI (normal/reference): 8.98
Ratio : 1.80	Ratio : 5.05



Contrast agent concentration curves

Blue curve: reference ROI (normal tissue)

Red curve: ROI within the lesion

Graph shows time-signal intensity curve over intratumoral ROI. There is an initial large decrease in signal intensity during first pass of gadolinium bolus, followed by a smaller signal intensity decrease (recirculation) and subsequent elevation of the signal intensity above baseline because of T1 effects associated with contrast material leakage into the extracellular space.

OLEA MEDICAL®

www.olea-medical.com

Olea Sphere® v3.0, medical imaging post-processing software, is a medical device manufactured and marketed by Olea Medical®. This medical device is reserved for health professionals. The software has been designed and manufactured according to the EN ISO 13485 quality management system. Read the instructions in the notice carefully before any use.

Instructions for Use are available on <http://www.olea-medical.com/en/> Manufacturer: Olea Medical® S.A.S. (France). Medical devices Class IIa / Notified body: CE 0459 GMED.

**IMPROVED
DIAGNOSIS
FOR LIFE**