

Lower limb sarcoma



Dr Anthony Sarran,
Institut Paoli Calmette, Marseille, France

Patient history

60-year-old man, self-examination of a mass in the posterior right thigh. Referred to pre-surgery examination.

Morphological findings

Findings using conventional sequences in MRI showed a heterogeneous lesion. The findings hereunder are being strongly suggestive of an aggressive lesion:

- deep seated tumor
- > 5 cm
- heterogeneous on T1 weighted before and after gadolinium (Figure 1)

The size and proximity of the tumor to the sciatic nerves prevented local excision with an adequate margin.

Post-processing and analysis

Dynamics maps such as Wash-in, Curve Wash-out, Peak, AUC (area under curve) were computed using the Extended Tofts model available in Olea Sphere® Application (Olea Medical®, La Ciotat, France). A multiparametric display (Permeability maps, T1, T2, ADC) available in Olea Sphere® was used to draw regions of interest and provide quantitative values of the lesion (Figure 2).

Permeability analysis

Perfusion curve shows a slow and low contrast enhancement and no wash-out (ROI 6) suggesting a benign tumor (Figure 3).

Histopathology diagnosis

Ultrasound-controlled percutaneous microbiopsy showed a fusiform cells tumor with morphological and immunohistochemical aspects documenting a benign schwannoma tumor.

Therapeutic decision

No surgery was planned, and decision was made for an active screening of this patient:

- Anatomopathological and functional imaging (diffusion and perfusion) documented a benign lesion.
- Aggressive surgery would have led to a sciatic nerve section for R0 (healthy margin) with disabling consequences.

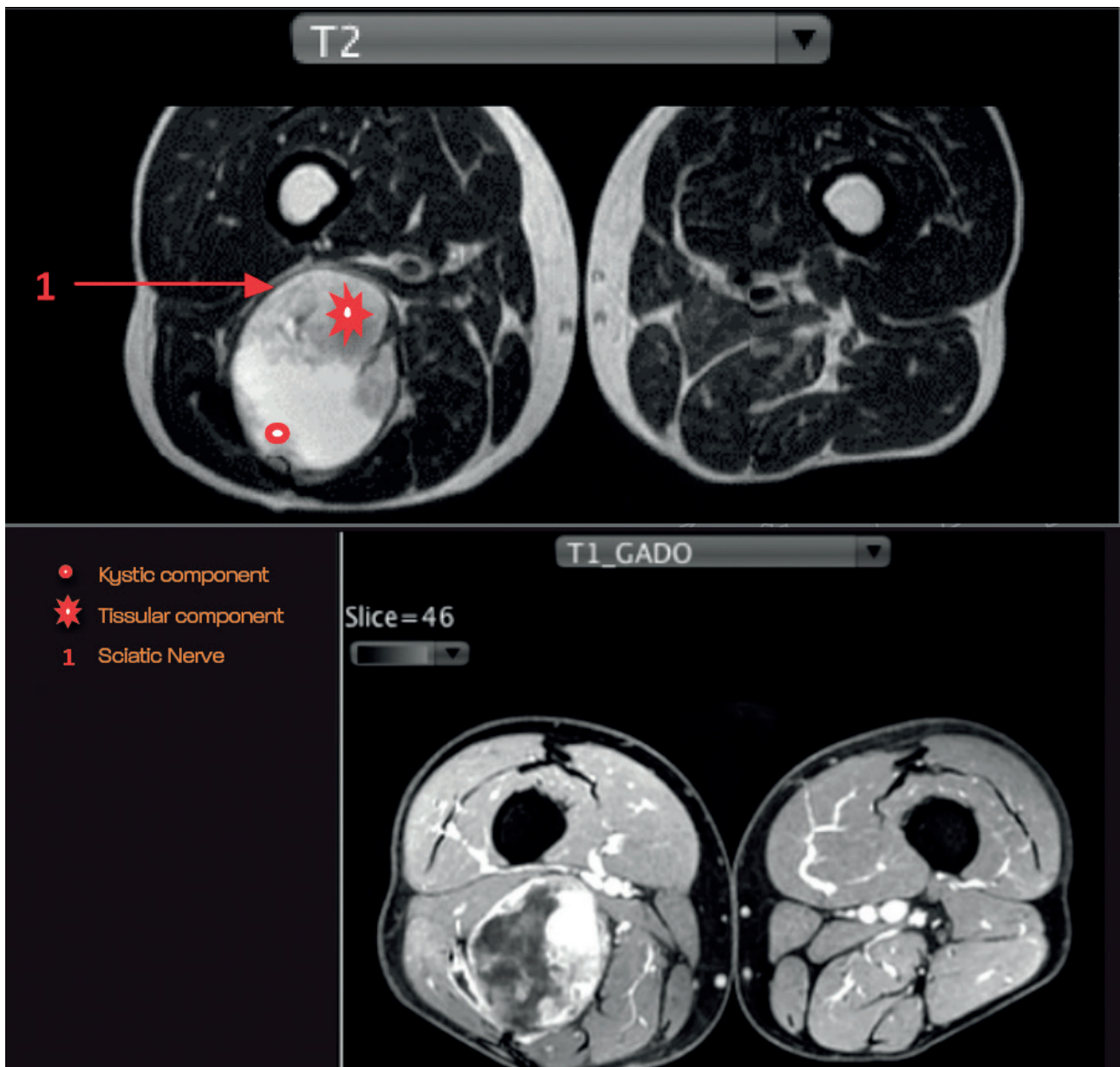


Figure 1 Right lower limb lesion: Axial T1 post contrast shows heterogeneous enhancement. Axial T2 shows a heterogeneous signal with cystic components

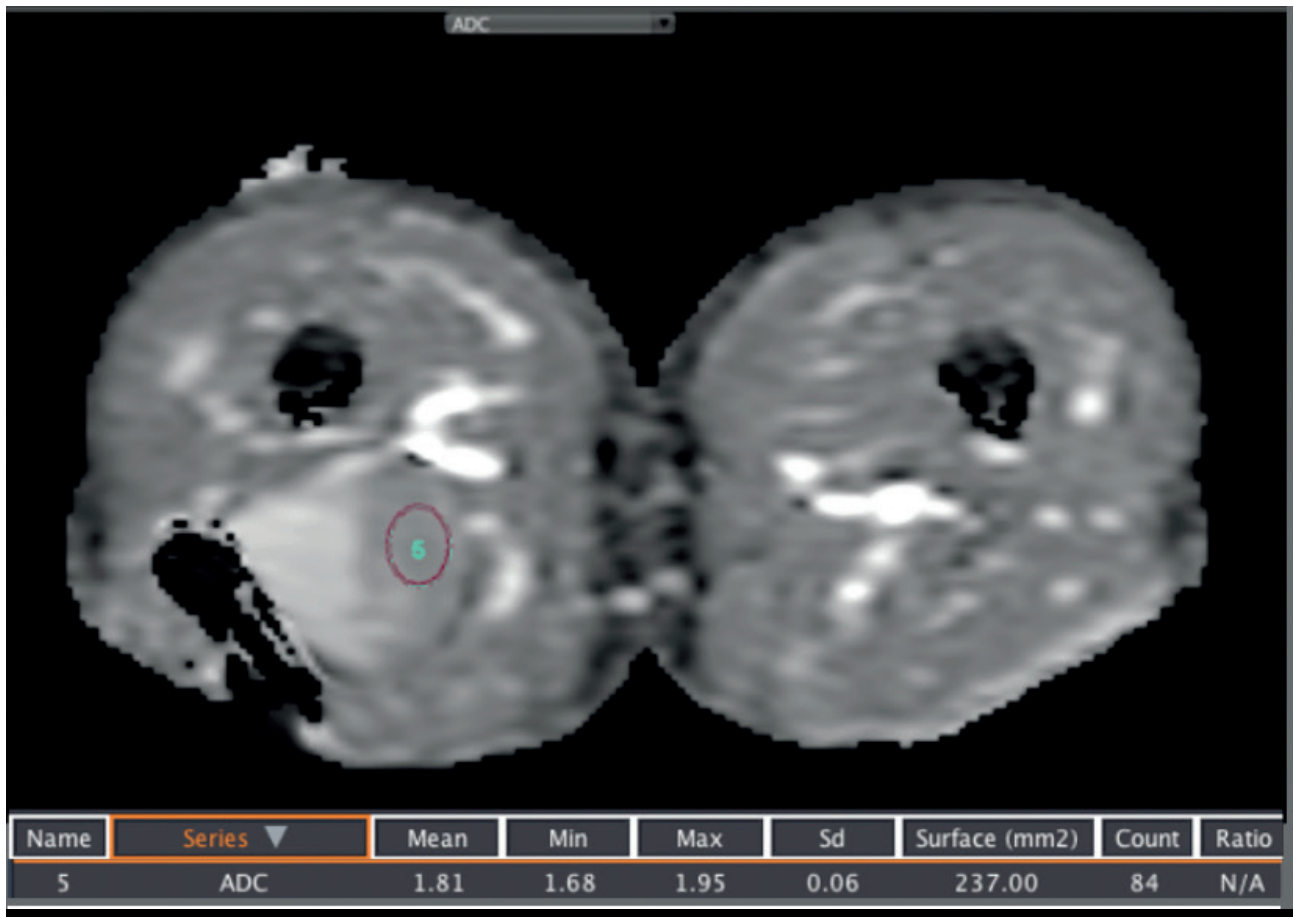


Figure 2 Mean value of the ADC (Apparent diffusion coefficient) in the Region of Interest (ROI 5) drawn in the tissue component: $1,8 \times 10^{-3} \text{mm}^2/\text{sec}$

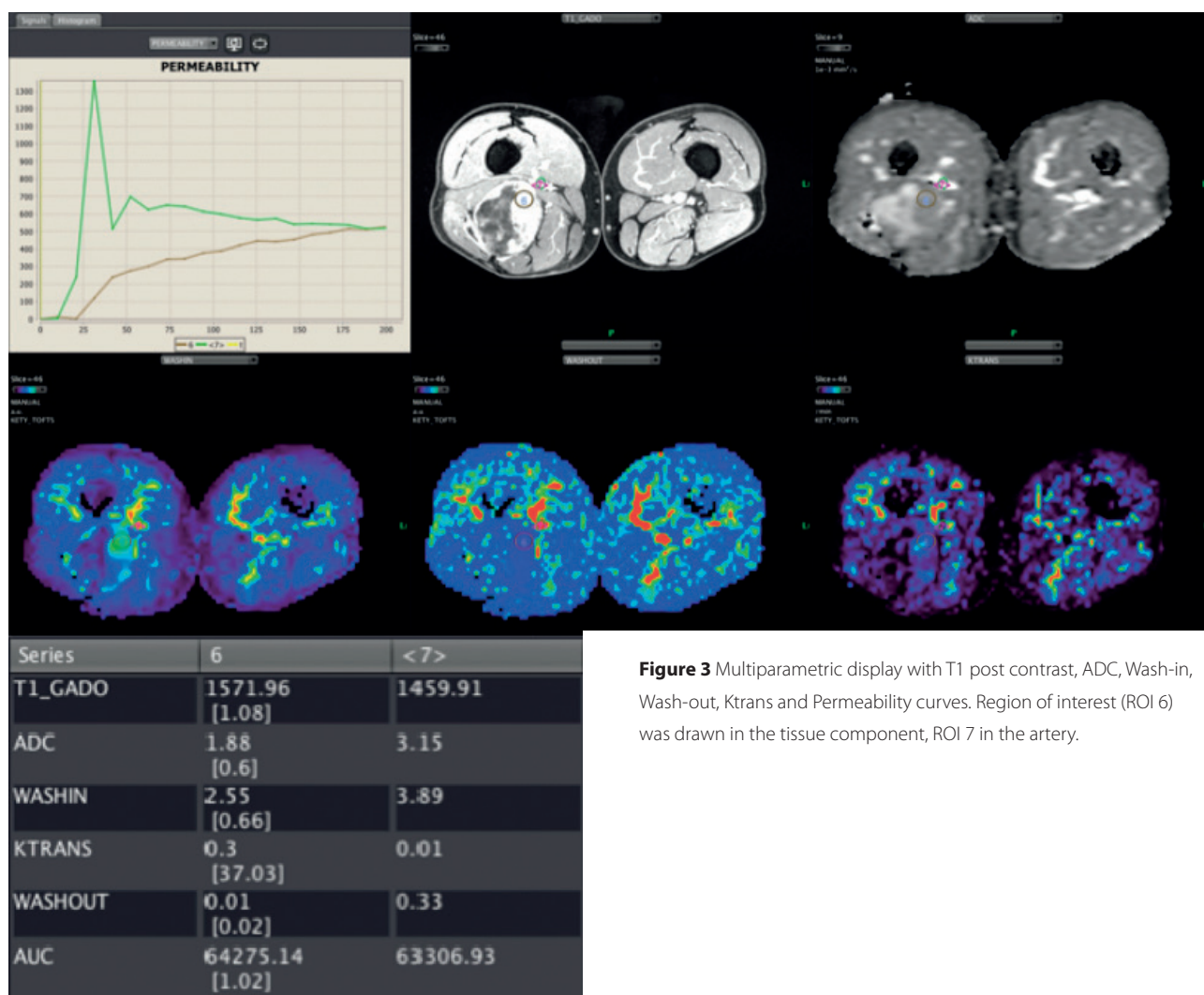


Figure 3 Multiparametric display with T1 post contrast, ADC, Wash-in, Wash-out, Ktrans and Permeability curves. Region of interest (ROI 6) was drawn in the tissue component, ROI 7 in the artery.

Conclusion

3 years later the patient remains asymptomatic and no lesion evolution is noted on MRI images. Combined DWI (diffusion weighted imaging) and PWI (perfusion weighted imaging) analysis provided essential and decisive information within the diagnosis process and therapy decision making.

OLEA MEDICAL®

www.olea-medical.com

Olea Sphere® v3.0, medical imaging post-processing software, is a medical device manufactured and marketed by Olea Medical®. This medical device is reserved for health professionals. The software has been designed and manufactured according to the EN ISO 13485 quality management system. Read the instructions in the notice carefully before any use.

Instructions for Use are available on <http://www.olea-medical.com/en/> Manufacturer: Olea Medical® S.A.S. (France). Medical devices Class IIa / Notified body: CE 0459 GMED.

**IMPROVED
DIAGNOSIS
FOR LIFE**