

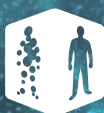# Olea Imagein MR evolution

P5  
Signature  
Index: a new  
promising  
parameter  
based  
on diffusion

P25  
fMRI: Imaging  
brain activity

P39  
Texture  
analysis: From  
methods to  
applications

P46  
Think outside  
the box:  
OleaCeption



**Olea**  
medical

#4 - October 2017 - JFR-RSNA Edition



<b>EDITO: Prof. Makoto Sasaki</b>	<b>P3</b>
<b>SIGNATURE INDEX: A new promising parameter based on diffusion</b>	<b>P5</b>
<b>Interview with Prof. Denis Le Bihan</b>	<b>P7</b>
<b>KURTOSIS: The non-Gaussian diffusion</b>	<b>P13</b>
<b>Interview with Prof. Zbigniew Serafin</b>	<b>P15</b>
<b>GLUCOCEST: Imaging glucose in MRI</b>	<b>P17</b>
<b>Interview with Prof. Xavier Golay</b>	<b>P19</b>
<b>fMRI: Imaging brain activity</b>	<b>P25</b>
<b>Interview with Prof. Andrei Holodny</b>	<b>P27</b>
<b>An inverse surface-based approach for cortical fMRI data projection</b>	<b>P31</b>
<b>SYNTHETIC MRI: Or how to play with contrast based on tissue properties</b>	<b>P33</b>
<b>Interview with Dr. Kambiz Nael</b>	<b>P35</b>
<b>TEXTURE ANALYSIS: From methods to applications</b>	<b>P39</b>
<b>Interview with Dr. Ashley Williams</b>	<b>P41</b>
<b>MSK &amp; SPORT IN MEDICINE: Interview with Prof. Mario Padron</b>	<b>P43</b>
<b>THINK OUTSIDE THE BOX: OleaCeption - Interview with Fayçal Djeridane</b>	<b>P46</b>
<b>DIGEST: Intravoxel incoherent motion (IVIM)</b>	<b>P50</b>
<b>TRADESHOWS &amp; WORKSHOPS</b>	<b>P52</b>
<b>PLAY TIME</b>	<b>P54</b>
<b>COMING NEXT</b>	<b>P55</b>

## EDITORIAL BOARD



**Anca Mitulescu, PhD**  
Director &  
VP Clinical Affairs  
Olea Medical®



**Sarah Quenet, MSc**  
Editor-in-Chief &  
Training and clinical  
support manager  
Olea Medical®



**Brianna Bucciarelli, MSc**  
Content manager &  
Clinical Research  
Engineer  
Olea Medical®



**Sophie Campana Tremblay, PhD**  
Content manager &  
Clinical & Scientific  
Research Engineer  
Olea Medical®



**Yasmina Chaibi, PhD**  
Contributor &  
Clinical & Scientific  
Research Manager  
Olea Medical®



**Sergiu Lescic, PhD**  
Contributor &  
Clinical & Scientific  
Research Engineer  
Olea Medical®

### Legal representative:

Fayçal Djeridane  
Olea Medical® is a subsidiary  
of Toshiba® Medical Systems Corporation  
**Printer:** Création Communication  
Impression (CCI) – 9 avenue Paul Herault  
13015 Marseille – France

### Director:

Anca Mitulescu

### Editor-in-Chief:

Sarah Quenet

### Content Managers:

Brianna Bucciarelli  
& Sophie Campana Tremblay

### Graphics:

Christophe Rebesco

### Reviewer:

Thomas Salnot

### Selling price:

Free of charge

### Date of legal deposit:

October 2017

### Publication date:

October 1st, 2017

ISSN Number: 2492-7260

According to the French Data Protection Act  
of January 6<sup>th</sup> 1978, modified in 2004, you have  
a right of access to and rectification of all of  
your personal data.

If you wish to exercise this right, please send  
your request by e-mail to the Marketing  
department of the company:

**contact@olea-medical.com**

You can also object, for appropriate reasons,  
to the processing of your personal data.

Olea Medical® is a French *société  
anonyme* governed by an executive board  
and a supervisory board  
with a share capital of € 2,040,526.

### Registered office:

93 avenue des Sorbiers - ZI Athélia IV 13600  
La Ciotat, France





# **Makoto Sasaki, MD, PhD**

*Director of the Institute for Biomedical Sciences,  
Iwate Medical University, Yahaba, Japan.*

My first encounter with Olea Medical® was in a teleconference regarding dynamic susceptibility-contrast perfusion imaging in early 2010. We discussed how to validate the accuracy and robustness of their former software, PerfScape®/NeuroScape®, because my colleague, Dr. Kohsuke Kudo, and I were attempting to benchmark various perfusion programs using our original digital phantoms. During the conference, they informed us of their exciting plan to develop a novel algorithm that uses Bayesian estimation. This algorithm may solve major issues affecting classical deconvolution algorithms for perfusion imaging. After optimization through intensive and meaningful meetings and communications, the Bayesian algorithm was finally implemented in Olea Sphere®. Through validation studies with digital phantoms and primate models, we were delighted to find that this innovative method dramatically improves the accuracy and robustness of perfusion imaging (for details, see Olea Imagein Issue Number 1, March 2016).

This is, however, only the beginning of “MRevolution” by Olea Medical®. They have applied and are applying the Bayesian approach into post-processing for various advanced MR techniques including relaxometry with T1/T2/T2\*/T1rho-mapping, intravoxel incoherent motion imaging, diffusion kurtosis imaging, synthetic MRI, and functional MRI. Furthermore, Olea Medical® is planning to develop Olea Sphere® as a next-generation comprehensive platform for image analysis and assessment by adding many innovative features including automated segmentation, elastography, and thermometry. I also hope that we will soon develop an optimized quantitative susceptibility mapping application that can accurately measure iron concentrations and oxygen extraction fractions in the brain.

I am very pleased to have the opportunity to form intimate collaborations with many friends of Olea Medical®, and I hope that these fruitful partnerships can advance the development of medical imaging.

Enjoy your reading of this “MRevolution” issue!



# Olea Innovators

3<sup>rd</sup> Edition of the Innovation award

## Goal

To encourage the advancement of an innovative MRI imaging technique for improved diagnosis for critical diseases

## Prizes

Integration in Olea Sphere® product  
**OR** a €10.000 grant

Competition details and rules available on [www.olea-medical.com/en/olea-innovators](http://www.olea-medical.com/en/olea-innovators)



Improved diagnosis for life™

Partner of Olea Innovators 3<sup>rd</sup> Edition *Inria*  
INVENTORS FOR THE DIGITAL WORLD



## Signature index:

### A new promising parameter based on diffusion



The concept behind the Sindex approach was proposed by Prof. Le Bihan in 2016 [1]. This novel approach leans on the identification of tissue types (e.g. benign or malignant lesions) directly from a distance between their diffusion MRI signal patterns (signal decay with the b-value, which is sensitive to Gaussian (free) and non-Gaussian (hindered) diffusion and perfusion through the IVIM effect) and a library of reference signal patterns from known tissues.

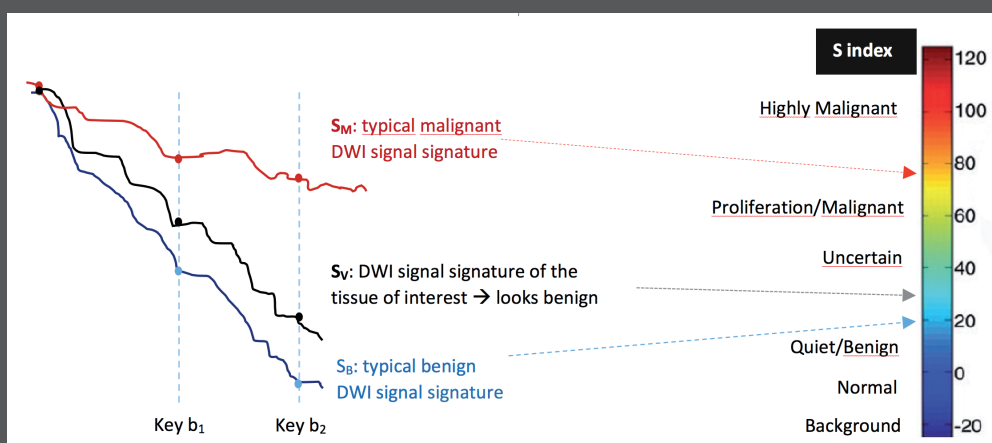
No model or fitting is necessary, making this Artificial Intelligence approach straightforward and fast. Those reference signals can be readily obtained from a database of patients with proven lesion types, leading to typical signals decays for each lesion type, an approach similar to that used for "big data". Theoretical signal patterns can also be generated based on various diffusion models (such as the Kurtosis model) and associated model parameter estimates found in the literature for different lesion types.

Interestingly, tissue identification could be obtained from a limited set of signals acquired only as specific b-values, called key b-values, chosen in order to maximize sensitivity to diffusion parameters to tissue features [1]. As an example, it was shown that the use of 200 and 1500 s/mm<sup>2</sup> b-values was the most suitable to characterize benign or malignant lesions in the breast [1]. As only 2 b-values are necessary, acquisition times are kept to a minimum.





Once the key b-values are identified, the quantitative absolute Sindex can be built by calculating a “distance” (algebraic distance, correlation coefficient, scalar product, etc.) between these typical signature tissue signals and the signals obtained from a voxel (or region of interest) in a tissue under investigation at these key b-values. These “distances” are then used to generate a Sindex scale that gives an indication of the tissue nature (malignant, benign, liquid, etc.) (Figure 1).



**Figure 1:** Principle of Sindex approach. Using only the voxel or region of interest signal acquired at 2 key b-values (SV), an absolute Sindex scale can be derived by comparing this signal with the known typical malignant (SM) and benign (SB) DWI signature signals obtained at these key b-values [3].

The results presented in Lima and Le Bihan study [1] demonstrate that Sindex is fast to compute and provides a good sensitivity and specificity for the identification of tissue pathological state. Moreover, the principle of Sindex could be applied successfully in a broad spectrum of applications such as IVIM angiography, IVIM lactography or IVIM elastography [2,3], which highlights the high potential in medical diagnostics of this innovative approach.

Sergiu Lescic

#### References

1. Lima M, Le Bihan D. Clinical Intravoxel Incoherent Motion and Diffusion MR Imaging: Past, Present, and Future. *Radiology*. 2016
2. Le Bihan D, Ichikawa S, Motosugi U. Diffusion and Intravoxel Incoherent Motion MR Imaging—based Virtual Elastography: A Hypothesis-generating Study in the Liver. *Radiology*. 2017 [Ahead of print]
3. Le Bihan D. IVIM-Élastographie virtuelle par IRM: principe et potentiel clinique. In: Proceedings of the Annual Meeting of JFR 2016 (Paris, France).



# Signature index



**Denis Le Bihan, MD, PhD**

*Founding Director of NeuroSpin,  
CEA Saclay-Center, Gif-sur-Yvette, France.*

Denis Le Bihan has gained international recognition for his outstanding contributions to the development of diffusion MRI methods. He is a full member of the French Academy of Sciences and currently the Founding Director of NeuroSpin, an Institute focusing on developing and using ultra high field Magnetic Resonance to better understand brain functions.

He has authored or co-authored over 250 articles, book chapters and review articles, and filed more than 10 patents in the fields of MRI, neuroscience and radiology. In 2001, he was awarded the Gold Medal of the International Society for Magnetic Resonance in Medicine. He is also the 2002 recipient of the Lounsbery Award from the National Academy of Sciences (USA) and French Academy of Sciences, a 2003 corecipient (with S. Dehaene) of the prestigious Louis D. Award of the Institut de France, and Honda Award. Denis Le Bihan is Knight of the French National Order of Merit.



**Olea Imagein:** You recently introduced a new approach derived from Diffusion metrics, able to classify tissues based on their “signature”. Could you please briefly explain the concept behind this Signature Index?

**Denis Le Bihan:** Many people in the world use Diffusion MRI, but the processing required to generate proper contrasts may be complex. Many signals obtained at different degrees of diffusion-weighting – so called b-values, have to be collected and then used to fit the signals with equations which are approximate models. Multiple parameters can then be derived such as  $ADC_0$ , which represents Gaussian diffusion in tissues, and the Kurtosis, which indicates how far the signal deviates from Gaussian or free diffusion – and so interactions of water molecules with obstacles, such as cell membranes. Besides, the complexity of the physical models results on long post-processing times.

The Sindex idea is very simple. If I look at you, I recognize you, right? And I know this without “equation”, without fitting, just face recognition from my brain. If I look at anyone, I immediately recognize him or her, just by looking at him or her, because each individual has a unique combination of facial features that describes him or her, a “signature”. This is the very simple concept behind Sindex. We consider reference tissues – for instance, in the breast, a typical malignant tissue and a typical benign lesion – and we obtain their respective signal profiles with diffusion MRI. Next, for a given patient, we just need to make a comparison between the signals acquired in a lesion and the signals of reference tissues by calculating the distance between those signal profiles. If the measured signal is close to malignant signal, the lesion is deemed malignant; conversely, if the measured signal is close to benign signal, the lesion is considered as benign: it is extremely simple.

This concept avoids the complexity of fitting with equations and models; moreover, it is fast since we discovered that this signature could be obtained from a very limited set of signals. By analogy, if I look at you, I can recognize you, maybe from your eyes and mouth, not your nose; I definitely do not need to analyze all the details. Similarly, we will just need signals acquired at “key” b-values: they

correspond to the degrees of diffusion-weighted which are the most sensitive to differentiate tissue features. We found that most often, two are enough, like the mouth and the eyes!

So, if we look at the signals at these two key b-values and compare them to the reference signals, the computed distance gives us the probability for the lesion to be malignant or benign. That is a “smart” index – although Sindex is for “signature” index, collected with a fast acquisition – only two b-values, and a fast processing – no fitting but a simple distance calculation.

**O.I:** The Sindex scale is combining the different phenomena, namely IVIM, Gaussian and non-Gaussian diffusion. In which proportion do these phenomena influence the signature?

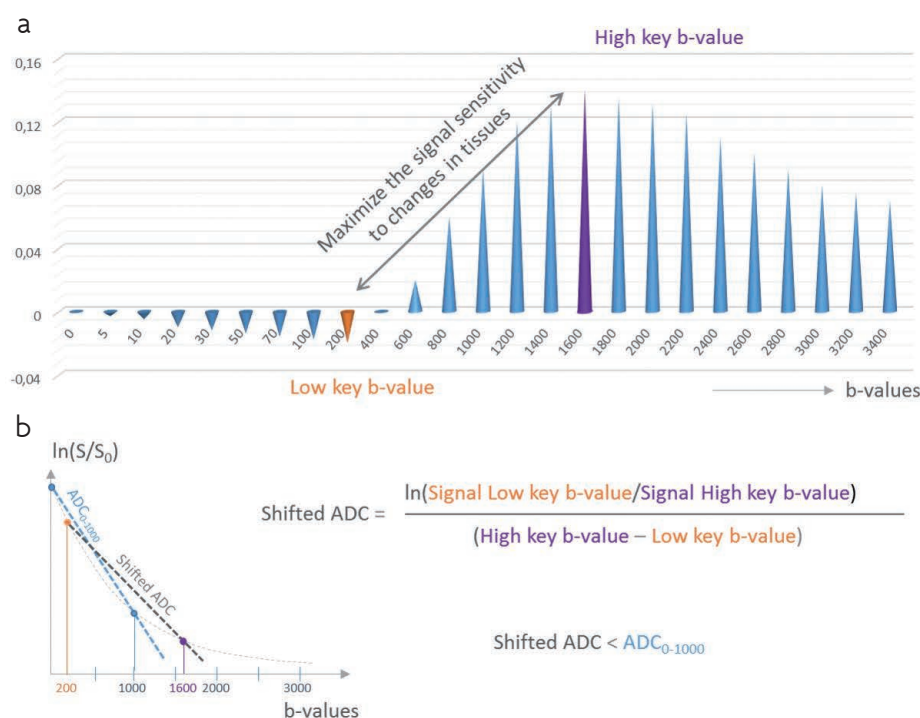
**D.L.B:** That is a good question. IVIM shows weaknesses, since we discovered that IVIM was not that strong in differentiating malignant and benign lesions even if, of course, some differences can be highlighted. Therefore, the most important discriminant biomarkers are  $ADC_0$  – Gaussian diffusion, and Kurtosis – non Gaussian diffusion.

“

Sindex is tunable

”

In setting up the key b-values, we maximize the sensitivity to changes in those components in an equal way, because we showed that both provide important information. However, we can change these contributions: if we want to design a Sindex which is more about non-Gaussian diffusion, we will use higher key b-values. If we want free diffusion to be more weighted, we just need to use lower key b-values. For the breast, typical key b-values are 200 and 1500 s/mm<sup>2</sup> corresponding to a well-balanced contribution between free and non-Gaussian diffusion. But again, this is tunable.



**Figure 1:** Selection of key b-values and Shifted ADC. a) Sensitivity of diffusion-weighted signal according to the b-values; low and high key b-values identified in orange and purple respectively maximize this sensitivity to changes in tissues, for an optimal differentiation of tissue types. b) Shifted ADC, inferior to standard ADC computed for 0 and 1000 s/mm<sup>2</sup> b-values, is assessed based on the two key b-values; it intrinsically includes the best differential sensitivity to tissue structure [1].

**O.I: In practice, how are the key b-values selected?**

**D.L.B:** They are assessed both experimentally and theoretically. We consider a small number of patients with proven malignant and benign lesions. Next, we look at the signals derived from these two sets of patients in order to define their key signatures. Then, using a diffusion physical model – once for all, only for those reference data – we change the parameters by, for instance, 5 or 10% for each b-value and we define which b-value gives the highest changes in the observed signal. So, we use experimental data collected on a small sample of patients and then a mathematical equation to derive the most sensitive b-values.

These values are organ-dependent for sure. Brain and body tissues behave differently in regards to diffusion. Within the body – breast, liver, prostate – key b-values are very close, even though not exactly similar.

There are therefore basically two different regions to consider: brain and neural tissues on one side, and the other body organs on the other side.

**O.I: What are the main advantages behind this concept? When do you believe the technology will be mature enough for widespread medical use?**

**D.L.B:** The first and most important point is that you only need to collect a few signals, therefore it is fast in terms of acquisition and patient time, a premium for clinical imaging!

The second point is that there is no requirement for any mathematical or physical model; so I think that clinicians might like the concept. It is therefore less sensitive to noise and less prone to potential errors in the calculations, and allows real-time processing.



This means that the patient could still lie in the magnet, you would get the images and immediately basically make a diagnosis. In case you are not satisfied, you could go on with further acquisitions if needed, perhaps injecting a contrast agent, and get the results while the patient is still in the machine. I believe this is a revolution!

“  
You could get the results while  
the patient is still in the machine.  
I believe this is a revolution!  
”

As for a widespread clinical use, as usual, we need validation. This means that hospitals have to try this idea on numerous patients with various diseases and different organs. This takes time. Diffusion took 20 years to be fully validated and commonly accepted, IVIM took 20 years also, but I hope that now it will go faster since it is based on something that people know: Diffusion MRI.

In any case, we need validation, maybe 200 or 300 patients for breast, and a similar number for the prostate. So now, it is just time. Most people are convinced that there is a potential interest, they just need to collect data. If you have a software available, like yours (*laugh*), then it will be easy for them to check the Sindex validity. In summary, we need to widely collect data on a large cohort to validate before clinical use.

**O.I: What does the scale correspond to?**

**D.L.B:** The scale was defined first to differentiate malignant and benign lesions. A typical (average) malignant lesion was set to 75 and a typical benign lesion to 25. It is a completely absolute scale. Malignant lesions will have scores from 50 up. Above 75 malignancy is “higher” than our typical reference cancer tissues, we have found lesions with an index of 150 in some spots. A nice feature of the Signature Index approach is that we get maps of the Sindex, showing heterogeneity, which can also be quantified. Below 20 or 15 we find normal tissue, and the Sindex goes to 0 or negative values for cysts. Therefore the index helps you

characterizing the lesion, like with the Hounsfield units for CT or SUV for PET, which tells directly the nature of the tissue. I think it is quite useful.

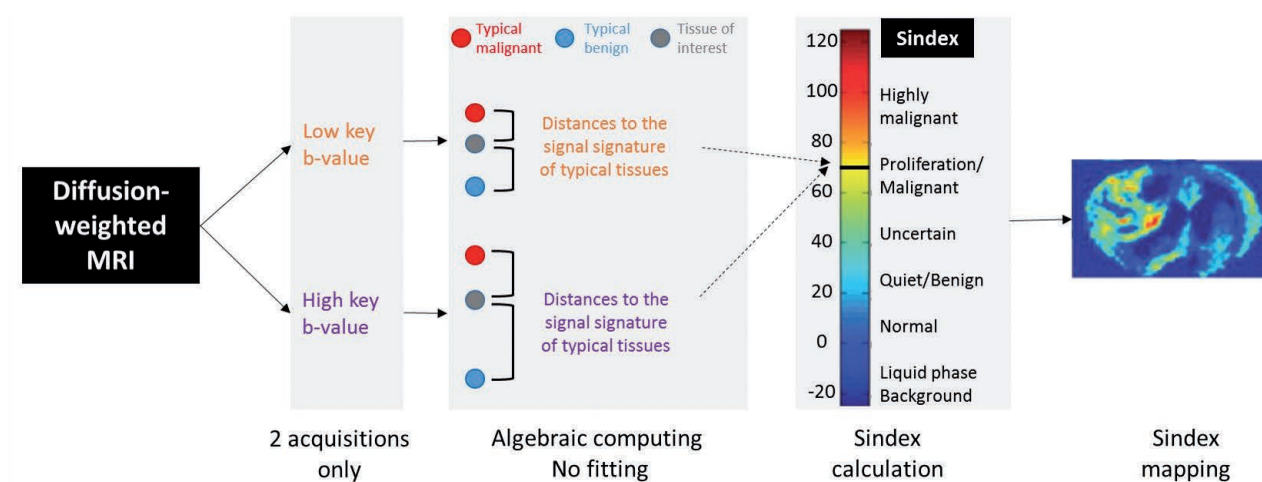
**O.I: Do the key b-values correspond to what is done today in clinical routine? If not, should both acquisitions be achieved?**

**D.L.B:** No, they do not necessarily correspond to the values used in clinical routine. Let’s look at the biomarker I introduced 30 years ago: the ADC. ADC is usually calculated between  $b=0$  and  $b=1000$   $s/mm^2$ , at least in the brain, because it can be shown that they are optimal in terms of signal to noise ratio. However, the ADC is poorly sensitive to non-Gaussian diffusion. In the breast, signal to noise considerations lead to  $b=0$  and  $800$   $s/mm^2$  for the ADC. But again, we miss non-Gaussian diffusion effects, although we now know they are so important for diagnosis and staging. Basically, we now need to get the ADC using “shifted” key b-values, for instance  $200$  and  $1500$   $s/mm^2$ . To avoid the confusion, I suggested to call this new ADC a “shifted” ADC, or sADC. Hence, protocols will have to be adapted; I know this is difficult for people to switch what they are used to do, but if they are convinced about the utility of this shift, hopefully they will do it.

**O.I: Which direct clinical applications do you expect, inside and outside the brain? Which new technologies could be derived from the use of the Sindex?**

**D.L.B:** The main application we foresee so far is oncology, to distinguish lesions between malignant and benign states; I think that is the obvious need. But Sindex can be scaled, which means that once you know a lesion is malignant, you can compute another Sindex to differentiate between several kinds of malignancies. Instead of having a signature between malignant and benign only, you can have a signature between type A and type B cancer, using another Sindex. The Sindex is a general concept; I gave the example of benign and malignant but it could be tuned to inflammation versus something else. The main application will be oncology: cancers in the breast, the prostate, and so on.

In the brain, we are working for instance on applications to detect the effect of radiations. Patients with tumors sometimes have radiotherapy, which can cause side effects such as cognitive impairment. We



**Figure 2:** Sindex absolute scale workflow, from acquisition to mapping. The Sindex reflects the proximity of the lesion signal to the signal signature of typical tissues (e.g. malignant, benign, liquid, etc).

have demonstrated on animal models that with the Sindex, we can highlight the effect of radiations on normal brain tissues, perhaps suggesting why people have those problems of cognitive impairment.

“

The Sindex is a general concept; I gave the example of benign and malignant but it could be tuned to inflammation versus something else.

”

could obtain beautiful 3D angiograms, just based on this idea, without contrast agents.

Another emerging field is elastography. We have shown that there is a very strong relationship between diffusion and elastic properties of tissues; this is not a surprise since both are related to the microstructure of the tissue. If you design the Sindex so that it recognizes low and high tissue elasticities, you can get elasticity values in kPa, exactly like MRE; except that in this case, there is no vibration, no hardware, no software for elastography. Therefore, the potential is huge.

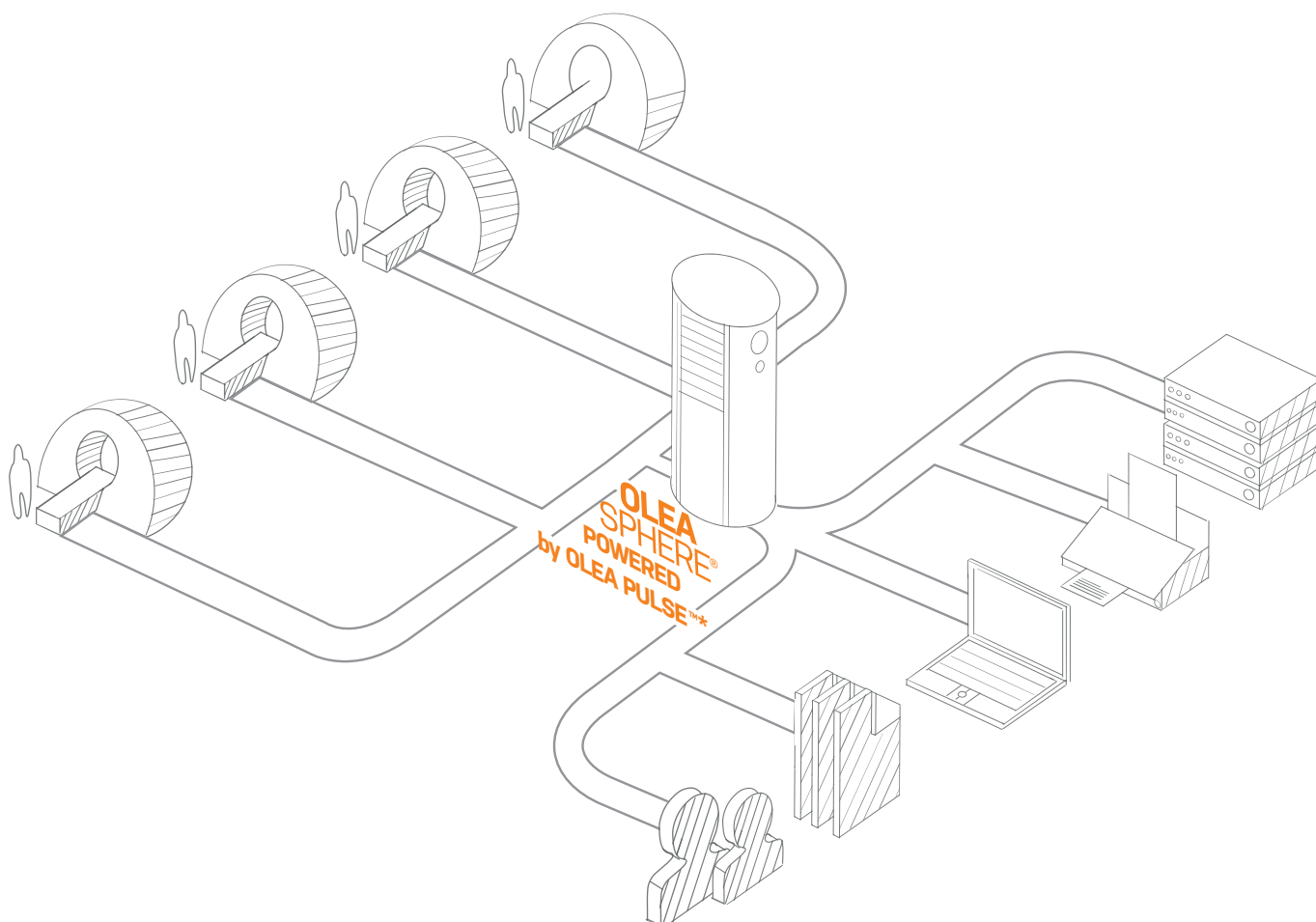
1. Iima M, Le Bihan D. Clinical Intravoxel Incoherent Motion and Diffusion MR Imaging: Past, Present, and Future. *Radiology*. 2016 Jan;278(1):13-32.

Interview by Sophie Campana Tremblay

We could also obtain a signature of blood vessels, to achieve what is called “IVIM angiography”, or angioIVIM, without injection of any contrast agent. We could tune the Sindex to detect the vessels; therefore, within a lesion, we could determine for each pixel which one belongs to vessel type and which one belongs to tissue type. As a result, we



# Bring automation to your post-processing



## Olea Pulse™\*

MULTI-VENDOR. MULTI-SCANNER. ONE SERVER

See Pr. Rovira's testimonial on Olea Medical® YouTube channel  
For more information: [www.olea-medical.com](http://www.olea-medical.com)

\*Olea Pulse™ is the offline processing service of Olea Sphere® v3.0



Improved diagnosis for life™

# Kurtosis: The non-Gaussian diffusion



MR diffusion kurtosis imaging (DKI) has been developed to probe the non-Gaussianity quantification of random water molecules displacement arising from the presence of complex and restricted structures in tissues; this phenomenon is highlighted when high b-values are used [1]. The deviation degree from Gaussian distribution can be assessed from a dimensionless kurtosis index (K) [2]. A positive kurtosis refers to leptokurtic curves (higher peak and heavier tails), while a negative kurtosis involves platykurtic curves (lower peak and lighter tails). Although negative kurtosis is mathematically possible, the diffusion models indicate that kurtosis is always positive [2].

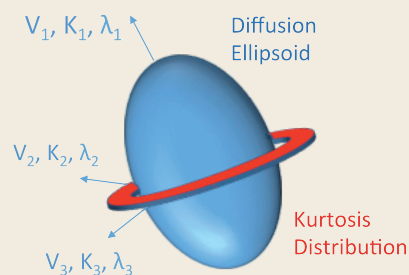
## Principle

DKI was introduced in the mid-2000s by Jensen et al. [3]. The key idea of their work was to estimate the DKI parameters from the Taylor expansion of logarithm diffusion-weighted signal  $S(b)$  in powers of b-values:

$$\ln[S(b)] = \ln[S_0] - bADC_0 + 1/6 b^2 ADC_0^2 K$$

Where:  $S_0$  is the theoretical signal intensity for a zero b-value;  $ADC_0$  and K are the apparent diffusion and kurtosis coefficients along a certain diffusion direction.

For an accurate estimation of diffusion DKI parameters with this model, zero b-value (for the reference signal) and at least two high b-values (e.g. 1000 and 2000  $s/mm^2$ ) are required [4]. Furthermore, due to the anisotropy of water diffusion in biological tissue,  $ADC_0$  and K need to be described as tensors [2,3].  $ADC_0$  can be captured by a  $3 \times 3$  tensor and visualized as an ellipsoid distribution; the modeling of K involves a fourth-order 3D symmetric tensor and represents a more complex spatial distribution (Figure 1).



**Figure 1:** Kurtosis distribution in relation to diffusion ellipsoid.  $V_1$ ,  $V_2$  and  $V_3$  are eigenvectors;  $\lambda_1$ ,  $\lambda_2$  and  $\lambda_3$  are eigenvalues of diffusion tensor;  $K_1$ ,  $K_2$  and  $K_3$  are kurtosis values along principle directions of diffusion ellipsoid [2].

1. de Santis S, Gabrielli A, Palombo M, Maraviglia B, Capuani S. Non-Gaussian diffusion imaging: a brief practical review. *Magn Reson Imaging*. 2011 Dec;29(10):1410–6.
2. Steven AJ, Zhuo J, Melhem ER. Diffusion kurtosis imaging: an emerging technique for evaluating the microstructural environment of the brain. *AJR Am J Roentgenol*. 2014 Jan;202(1):W26–33.
3. Jensen JH, Helpert JA, Ramani A, Lu H, Kaczynski K. Diffusional kurtosis imaging: the quantification of non-gaussian water diffusion by means of magnetic resonance imaging. *Magn Reson Med*. 2005 Jun;53(6):1432–40.
4. Jensen JH, Hu C, Helpert JA. Rapid Data Acquisition and post-processing for diffusional kurtosis imaging.

- Proceedings of the 17th Annual Meeting of ISMRM 2009 (Honolulu, HI, USA).
5. Wu EX, Cheung MM. MR diffusion kurtosis imaging for neural tissue characterization. *NMR Biomed*. 2010 Aug;23(7):836–48.
6. Hansen B, Lund TE, Sangill R, Jespersen SN. Experimentally and computationally fast method for estimation of a mean kurtosis. *Magn Reson Med*. 2013 Jun;69(6):1754–60.
7. Tabesh A, Jensen JH, Ardekani BA, Helpert JA. Estimation of tensors and tensor-derived measures in diffusional kurtosis imaging. *Magn Reson Med*. 2011 Mar;65(3):823–36.
8. Dyvorne HA, Galea N, Nevers T, Fiel MI, Carpenter D, Wong E, Orton M, de Oliveira A, Feiweiier T,

- Vachon M, Babb JS, Taouli B. Diffusion-weighted imaging of the liver with multiple b values: effect of diffusion gradient polarity and breathing acquisition on image quality and intravoxel incoherent motion parameters—a pilot study. *Radiology*. 2013 Mar;266(3):920–9.
9. Struyfs H, Van Hecke W, Veraart J, Sijbers J, Slaets S, De Belder M, Wuyts L, Peters B, Slegers K, Robberecht C, Van Broeckhoven C, De Belder F, Parizel PM, Engelborghs S. Diffusion Kurtosis Imaging: a possible MRI biomarker for AD diagnosis? *J Alzheimers Dis*. 2015;48(4):937–48.
10. Baumann PS, Cammoun L, Conus P, Do KQ, Marquet P, Meskaldji D, Meuli R, Thiran JP, Hagmann P. High b-value diffusion-weighted imaging: A

A full characterization of K tensor needs at least 15 diffusion directions for each acquired b-value, generating a relatively long acquisition time (7-10 minutes) and an increased susceptibility to patient motion [2]. Therefore, to make this approach less time consuming, only DKI parameters that have more direct physical relevance are commonly used [5], such as the **mean diffusivity** and the **fractional anisotropy**, as well as metrics related to the axial and radial kurtosis. By only computing mean kurtosis for example, the acquisition time can decrease up to 1-2 minutes [6].

This approach, together with IVIM (low b-values) and ADC (intermediate b-values), remains one of the most adapted model to describe the water diffusion signal attenuation in tissue.

DKI parameters are empirically estimated with the classical least squares methods [7]. However, they are time-consuming and prone to errors [7,8]. To overcome these issues, Olea Medical® is currently developing a Bayesian approach to estimate DKI parameters; rather than minimizing a residual error, the uncertainty of each parameter is calculated separately with a narrow probability density function, yielding a more accurate estimation in a clinically acceptable processing time [8].

### Medical applications

The ability of DKI to detect microstructural alterations was mainly highlighted in neuronal tissue. It has been reported that DKI was more sensitive than conventional diffusion-weighted imaging (DWI) for neurodegenerative diseases such as Alzheimer's [9], Schizophrenia [10], Parkinson's [11] or gliomas [12]. Encouraging results were also found for multiple sclerosis [13] and the characterization of cerebral infarction [14,15]. In case of cerebral ischemia, DKI could exhibit distinct ischemic lesion heterogeneity at an early stage that was not apparent on conventional DWI [15]. Besides neuroradiology, DKI approach has been shown to be useful for the investigation of lung [16], liver [17] and bladder [18] diseases.

Despite all the promising results, this powerful concept still belongs to the research field. Although it requires only minor changes in data acquisition compared to conventional DWI, the main limitation for a clinical routine use lies in the difficulty to acquire high b-values in MRI scanners. Nevertheless, the MRI hardware has considerably improved over the past years, allowing larger b-values to be available.

Sergiu Lescic

➤ for more information about Kurtosis, ADC and IVIM models, please refer to the second issue of Olea Imagein magazine [19]

sensitive method to reveal white matter differences in schizophrenia. *Psychiatry Res.* 2012 Feb 28;201(2):144–51.

11. Wang JJ, Lin WY, Lu CS, Weng YH, Ng SH, Wang CH, Liu HL, Hsieh RH, Wan YL, Wai YY. Parkinson disease: diagnostic utility of diffusion kurtosis imaging. *Radiology.* 2011 Oct;261(1):210–7.

12. Van Cauter S, Veraart J, Sijbers J, Peeters RR, Himmelreich U, De Keyser F, Van Gool SW, Van Calenbergh F, De Vleeschouwe S, Van Hecke W, Sunaert S. Gliomas: diffusion kurtosis MR imaging in grading. *Radiology.* 2012 May;263(2):492–501.

13. Yoshida M, Hori M, Yokoyama K, Fukunaga I, Suzuki M, Kamagata K, Shimoji K, Nakanishi A, Hattori N, Masutani Y, Aoki S. Diffusional kurtosis

imaging of normal-appearing white matter in multiple sclerosis: preliminary clinical experience. *Jpn J Radiol.* 2013 Jan;31(1):50–5.

14. Cheung JS, Wang E, Lo EH, Sun PZ. Stratification of heterogeneous diffusion MRI ischemic lesion with kurtosis imaging. *Stroke* 2012 Aug;43(8):2252–4.

15. Hori M, Fukunaga I, Masutani Y, Taoka T, Kamagata K, Suzuki Y, Aoki S. Visualizing non-Gaussian diffusion: clinical application of q-space imaging and diffusional kurtosis imaging of the brain and spine. *Magn Reson Med Sci.* 2012;11(4):221–33.

16. Trampel R, Jensen JH, Lee RF, Kamenetskiy I, McGuinness G, Johnson G. Diffusional kurtosis imaging in the lung using hyperpolarized <sup>3</sup>He. *Magn Reson Med.* 2006 Oct;56(4):733–7.

17. Rosenkrantz AB, Sigmund EE, Winnick A, Niver BE, Spieler B, Morgan GR, Hajdu CH. Assessment of hepatocellular carcinoma using apparent diffusion coefficient and diffusion kurtosis indices: preliminary experience in fresh liver explants. *Magn Reson Imaging.* 2012 Dec;30(10):1534–40.

18. Suo S, Chen X, Ji X, Zhuang Z, Wu L, Yao Q, Fan Y, Xu J. Investigation of the non-Gaussian water diffusion properties in bladder cancer using diffusion kurtosis imaging: a preliminary study. *J Comput Assist Tomogr.* 2015 Mar-Apr;39(2):281–5.

19. Chaibi Y, Bucciarelli B, Campana Tremblay S. The Diffusion Saga: for a good Sunday read. *Olea Imagein, Issue Number 2- March 2017. ECR Edition.* p.10-20.





# Kurtosis

## **Zbigniew Serafin, MD, PhD**

*Head of the Department of Radiology and Diagnostic Imaging at Medical College of Nicolaus Copernicus University, Bydgoszcz, Poland. Deputy Editor-in-Chief of the Polish Journal of Radiology.*

Zbigniew Serafin graduated from the Medical Academy of Bydgoszcz in 1998. He completed his PhD in computer tomography of the heart in 2005, and specialized in neuro imaging.

He is currently the head of the Department of Radiology and Diagnostic Imaging at the Medical College in Bydgoszcz, Nicolaus Copernicus University in Toruń, Poland.

His major research interests include multi-energy computer tomography and post-processing of MR diffusion images.

### **Olea Imagein: Could you please share with our readers the scope of your clinical interests?**

**Zbigniew Serafin:** First, I am a medical doctor. In my opinion, an everyday contact with clinical practice allows for a proper balance between “pure science” and “life”. I just need this (*laugh*). I started from interventional and cardiovascular radiology. Currently, I lead teams working on so-called positive brain aging multimodal MRI, vestibular system fMRI, colorectal liver metastasis imaging at dual energy CT, multi-parametric MRI of pancreatic cancer and contrast-enhanced ultrasound and MRI in patients with Crohn’s disease. As you can see, I deal with different anatomic regions but my scope is mainly signal post-processing.

At some point, I realized that our machines offer us a lot of information every day and we are using just a small part from that. An example may be computed tomography. For years we were using a polychromatic approach. Nowadays, leading vendors offer polyenergetic scanners, which allow a separation

of the signal according to selected photon energies. And suddenly we were shown an amazing spectrum of images, very different from each other. Can we use them in clinical practice? Well... not yet. The same goes for MRI. We are given a lot of scanning options and a lot of information. And we use just sizes, a relative contrast enhancement, and diffusion restriction. Measurable parameters, including T1 value, T2 value and ADC were still not able to come to the practice. There is a huge gap between a university scientist and a private radiology practitioner. I am trying to bridge that gap.

### **O.I: Could you please briefly explain the principles of Diffusion Kurtosis imaging and the reasons of your interest?**

**Z.S:** The concept was beautifully explained by Yasmina Chaibi, Sophie Campana Tremblay, and Brianna Bucciarelli in the 2nd issue of Olea Imagein. In summary, Diffusion Kurtosis Imaging (DKI) is just another way to post-process diffusion-weighted signal.

Conventional diffusion-weighted imaging (DWI) assumes that all water molecules in a voxel present the same Brownian motion. Of course, such an approach is a bit of an oversimplification but allows for rapid calculations and image presentation. This classic DWI became a standard part of MRI protocols and is an invaluable tool for imaging stroke, inflammatory diseases and neoplasms. However, as our post-processing computers are more and more powerful, we got the possibility to use more advanced mathematical models to present the diffusion-weighted signal.

DKI model accepts the fact that movement of water molecules present a non-Gaussian distribution under high b-values. In other words, when using the DKI model, we are able to increase our resolution to detect the differences in the water molecules velocity, and thus, local tissue properties that influence that movement. Those include all structural alterations on the cellularity that build barriers for diffusion. In fact, the precise translation of diffusion-weighted signal to particular processes in the extracellular and intracellular space is still being investigated.

**O.I: Why can Kurtosis be a biomarker? What does it reveal from the physiologic properties of tissues? Which quantification is still missing?**

**Z.S:** A good biomarker should be like a screening test: easy to use, reproducible and of high predictive value. Of course, DKI can be a biomarker and I hope it will be. However, there is a long way between a clever idea and an established biomarker.

“

A good biomarker should be like a screening test: easy to use, reproducible and of high predictive value.

”

DKI allows for calculation of several, somehow artificial, parameters of water diffusion. Those include tissue perfusion-related coefficient ( $D^*$ ), perfusion fraction (f), apparent diffusion coefficient (ADC), and apparent kurtosis coefficient (K). Each of them may be, or not, related to some pathological features of tissue. Current studies are focused on testing each of them under pathological

circumstances. This way, we are able to find a hypothetical connection between a disease and a DKI parameter. Still, a great effort is necessary to set an optimized and easy-to-use acquisition protocol, to verify the biomarker in a large population, and finally to promote the idea to clinicians.

Acquisition issues are, in my opinion, quite easy to overcome. DKI requires scanning using at least three b-values and “likes” high b-values. Therefore, scanner’s field strength and scanning time are important. The major issue for me, as a clinical radiologist, is post-processing. I am not an engineer and all the open source Linux software packages available for DKI which require command line use are too difficult to me. Therefore, the initiative of Olea Medical®, to release a DKI package is great news for me.

**O.I: What are the current and future applications of Diffusion Kurtosis imaging? What are your expectations regarding this technique?**

**Z.S:** As DKI is a recent modality, it is being tested for all possible applications. Currently, there are 233 papers on DKI indexed in PubMed and you can find almost every organ tested in them. This means that we are still in a fog. We have got a new imaging possibility and we are looking for any connection. Of course, it is a common problem of every developing imaging modality. To tell you the truth, I have no expectations regarding DKI. I am just testing it.

In practice, DKI may have an application in pathologies, which are related to a significant alteration of microstructure. Those include malignant neoplasms and chronic inflammation. Especially, prediction of tumor response after anti-vascular chemotherapy and differentiation between active inflammation and fibrosis in Crohn’s disease are of my interest. On the other hand, I doubt that DKI may be a biomarker for diffused diseases with subtle changes at the tissue level, like Alzheimer’s or Asperger’s diseases. So, in conclusion, what do I expect from DKI technology? I need a powerful post-processing software with multi-parametric options. Having that, we can bring DKI to practice.

Interview by Brianna Bucciarelli

## GlucoCEST: Imaging glucose in MRI



GlucoCEST, or Glucose-based chemical exchange saturation transfer, is a ground-breaking new MR technology expected to allow a less invasive, more accurate and earlier cancer detection.

### Why Glucose?

Due to the Warburg effect [1], cancerous cells generate their energy in the form of ATP (adenosine triphosphate) through aerobic glycolysis, a process that is not very efficient. In order to produce enough energy, the glucose metabolic rate is hence particularly high in the proliferative tissues. Glucose uptake assessment, as achieved with FDG-PET (fluorodeoxyglucose positron emission tomography), is therefore a key discriminator for tumors.

### CEST

The CEST (Chemical Exchange Saturation Transfer) effect was reported as early as 1951 [2,3]. After further advances in 1963 [4], the approach was adapted to *in vivo* NMR in 1990 by Wolff and Balaban [5].

The CEST method makes it possible to generate a contrast related to the exchange of protons between free water in the body and surrounding labile protons in molecules, often in much lower concentration than water [6].

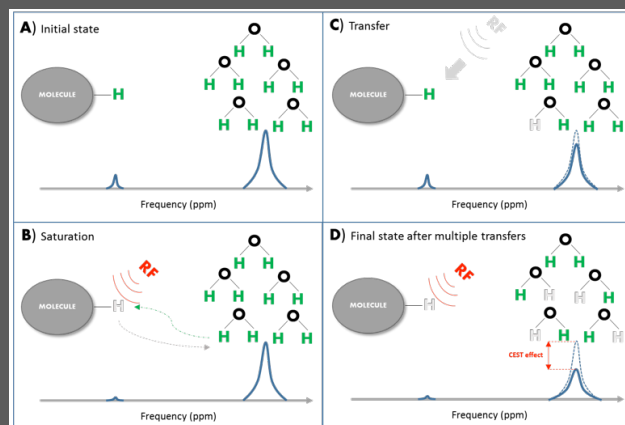
Let us consider an NMR spectrum figuring the signals of both water and labile proton-containing molecules, exposed to a magnetic field, on the frequency scale (Figure 1A). Using a radiofrequency (RF) irradiation, a proton from the chosen molecule is selectively saturated at its specific resonance frequency; as a consequence, the labile protons from the molecule's signal vanishes from the spectrum (Figure 1B).

At that moment, the CEST effect occurs: water and molecule exchange their respective protons, resulting in a saturation (or magnetization) transfer from the molecule to the water proton. In return, water now contains a saturated proton, and its signal slightly decreases on the frequency scale (Figure 1C).





A single exchange would not be sufficient to detect a significant change in water signal; but if this cycle is repeated long enough, if the T1 relaxation of the exchanged protons is within the right range and if numerous proton exchanges successively take place, the water signal variation will become substantially visible, indirectly revealing the presence of the chosen molecule (Figure 1D). The water signal difference between the initial and final state measures the concentration level of the molecule of interest, with a high enhancement factor or magnification phenomena.



**Figure 1:** CEST effect. Adapted from Prof. Xavier Golay, ECR 2017

### GlucocEST

Several teams around the world [7-9] concomitantly applied the CEST effect to the glucose molecule, resulting in a new imaging method able to detect glucose uptake by MRI: GlucoCEST.

With the saturated proton located on the hydroxyl groups of glucose, the chemical exchange with water takes place and the water signal is recorded before and after injection of nonradioactive glucose. The GlucoCEST enhancement is evaluated from the difference between both spectra.

*In vivo* studies have been reported on mouse colorectal tumors [9], rat brain [8] or mice breast cancer [7,10]. The ongoing GLINT European project aims to further develop the GlucoCEST method as a new diagnostic non-invasive tool for human cancer, and to establish the safety profile of other and potentially more efficient glucose analogues.

Sophie Campana Tremblay



1. Vander Heiden MG, Cantley LC, Thompson CB. Understanding the Warburg effect: The metabolic Requirements of cell proliferation. *Science*. 2009;324(5930):1029-1033.
2. Arnold T, Packard M. Variations in Absolute Chemical Shift of Nuclear Induction Signals of Hydroxyl Groups of Methyl and Ethyl Alcohol. *J Chem Phys*. 1951;19:1608-1609.
3. Liddel U, Ramsey N. Temperature dependent magnetic shielding in ethyl alcohol. *J Chem Phys*. 1951;19:1608.
4. Forsen S, Hoffman RA. Study of moderately rapid chemical exchange reactions by means of

- nuclear magnetic double resonance. *J Chem Phys*. 1963;39:2892-2901.
5. Wolff SD, Balaban RS. NMR Imaging of Labile Proton Exchange. *J Magn Reson*. 1990;86(1):164-169.
6. Van Zijl P, Yadav NN. Chemical exchange saturation transfer (CEST): what is in a name and what isn't? *Magn Reson Med*. 2011;65(4):927-948.
7. Chan K W Y, McMahon MT, Kato Y, Liu G, Bulte JWM, Bhujwala ZM, Artemov D, van Zijl P. Natural D -Glucose as a Biodegradable MRI Contrast Agent for Detecting Cancer. *Magn Reson Med*. 2012;68(6):1764-1773.
8. Nasrallah FA, Pagès G, Kuchel PW, Golay X,

- Chuang KH. Imaging Brain Deoxyglucose Uptake and Metabolism by Glucocest MRI. *J Cereb Blood Flow Metab*. 2013;33(8):1270-1278.
9. Walker-Samuel S, Ramasawmy R, Torrealdea F, Rega M, Rajkumar V, Johnson SP, Richardson S, Gonçalves M, Parkes HG, Årstad E, Thomas DL, Pedley RB, Lythgoe MF, Golay X. *In vivo* imaging of glucose uptake and metabolism in tumors. *Nature Med*. 2013;19(8):1067-1072.
10. Rivlin M, Navon G. CEST MRI of 3-O-methyl-D-glucose on different breast cancer models. *Magn Reson Med*. 2017 [Ahead of print].



## GlucocEST

### **Xavier Golay, PhD**

*Professor of MR Neurophysics and Translational Neuroscience, Vice Dean for Innovation and Enterprise of the faculty of Brain Sciences and Head of the Department of Brain Repair and Rehabilitation at the University College London (UCL) Institute of Neurology in Queen Square, London, UK.*

After receiving an MSc in Physics, Xavier Golay completed his PhD on functional MRI in 1998 and worked with Prof. Peter van Zijl on neuroimaging and spectroscopy projects as a post-doctoral fellow at Johns Hopkins University in Baltimore (Maryland, USA). He became a Research Associate and then an Assistant Professor in the Department of Radiology at John Hopkins School of Medicine.

In 2003, he moved to Singapore at the National Neuroscience Institute, developing clinically relevant arterial spin labeling techniques. In 2005 he took up the position of Head of the Laboratory of Molecular Imaging at the Singapore Bioimaging Consortium.

Since 2008, Xavier Golay is the Chair of MR Neurophysics and Translational Neuroscience at the UCL Institute of Neurology in London. In 2012, he was promoted to the position of Head of the Department of Brain Repair and Rehabilitation. The same year, he was elected President of the European Society for Magnetic Resonance in Medicine and Biology (ESMRMB). He is currently the scientific coordinator of the GLINT European project.

He is the author or co-author of over 130 scientific articles and 15 review articles / book chapters on MRI, and member of the Editorial boards of Magnetic Resonance Materials in Physics, Medicine and Biology (MAGMA) and Nuclear Magnetic Resonance (NMR) in Biomedicine.

His research interests lie at the intersection of many disciplines, such as NMR physics, chemistry, physiology and neuroscience. They include the development of MRI as a translational tool for neurological diseases, measuring identical image-based biomarkers from mouse to human, and from the laboratory to the clinical settings.

**Olea Imagein:** Your research contributions cover broad clinical areas in MRI, with a special focus on metabolic imaging. Could you please share with our readers how your background led you to get interested in the particular GlucoCEST imaging process?

**Xavier Golay:** It all probably started 20 years ago, during my PhD on functional MRI (fMRI). When looking at fMRI, we were interested in trying to decompose the signal into blood flow, blood volume and oxygenation. I spent 10 more years of my life working on quantitative fMRI, basically looking at oxygenation changes during activation, and particularly oxygen metabolism.

But, while the oxygen metabolism is important, cells can actually work without oxygen, and as such, glucose metabolism would be one step closer to the understanding of *in vivo* cell function. I always had that in the back of my mind, knowing that the existing NMR-based methods, used with injection of carbon-13 glucose or other metabolites, do not provide enough signal to be able to produce real images.

In the meantime, I had spent several years at Johns Hopkins University where Peter van Zijl was starting to be interested in the CEST (Chemical Exchange Saturation Transfer) effect. When I moved to Singapore, I read an article by Peter about the use of CEST to image glycogen in the liver. In this paper, he made the point that the CEST spectra of both glycogen and glucose were slightly different, and he had a few graphs showing the CEST spectra, also called the Z spectra, of glucose.

By looking at these results, I wondered if we could follow glucose changes in the brain – I first thought about the brain, since it was at that time my main focus – by using this method. Since I was also working with Prof Georges Radda, in charge of the Singapore Bioimaging Consortium, we thought that it would be probably easier to use 2-deoxyglucose as a contrast agent, as it is a glucose analogue that gets phosphorylated by the hexokinase enzyme without undergoing any further metabolic transformation, and therefore accumulates intracellularly. We hypothesized that, in such a case, we could detect a stronger signal than when using normal glucose, which would disappear rather rapidly through cellular glycolytic processes.

Therefore, we started working on this, and it took a few years to optimize all animal handling, injection schedules and imaging methods.

“

I realized that, in addition to the brain, one of the main applications for glucose imaging could be in cancer.

”

When I moved from Singapore back to Europe, where I took a position of Professor at UCL, I realized that, in addition to the brain, one of the main applications for glucose imaging could be in cancer. Then we tried both glucose and 2-deoxyglucose, and it seemed that even with glucose, we could see very strong signals when applied to cancers, unlike in the brain, where the signals were much smaller and disappearing rapidly. This finding led to the publication of two articles in 2013, one using 2-deoxyglucose in the brain of rats, the other using glucose in mice tumors. The whole development to reach that stage took us around 5 years, including the sequence optimization and the understanding of the whole biochemistry linked to the glucose metabolism. We ran many experiments, compared our measurements with pretty much everything we could, from perfusion to oxygenation and pH assessment using phosphorus spectroscopy, among others, to ensure that the signal detected was primarily coming from glucose accumulation.

**O.I:** Could you please describe the fundamentals of the GlucoCEST method? How different is it from other molecular imaging techniques?

**X.G:** Regarding the methodology, GlucoCEST is using CEST or Chemical Exchange Saturation Transfer, which is an imaging method based on the exchangeable proton groups on molecules, indirectly detected through the water signal by transferring the magnetization from these protons to the water molecules. By doing this over and over again, if you assume that you have a small amount



of these molecules in a large amount of water surrounding it, you can end up with a chemical amplification factor that actually allows you to image indirectly millimolar concentrations of molecules. This is a massive amplification factor, around three orders of magnitude. GlucoCEST is just actually about looking at the 5 hydroxyl groups on the glucose molecules, which all exchange relatively rapidly at around 2000 Hz, and are therefore within the detection range allowed by the CEST boundary conditions. You can image the patient before and after injection of glucose, or you can completely follow the glucose concentration curve, by doing some kind of dynamic glucose enhancement imaging like you would do with Gadolinium, but using a biodegradable contrast which is not toxic for the body.

So, how does it differ from other molecular techniques? I am going to tell you a secret here: it is not a molecular imaging technique, not according to the usually accepted definition. Molecular imaging needs to report on a biological factor, typically an abundance of receptors somewhere, without modifying the biology of the organ analyzed. In our case, it is a very different type of imaging because what is injected is a metabolically active substance that will directly affect the metabolism. We do use glucose in this case not in tracer concentration, but in substrate concentration, to assess the reaction of the organ to a real amount of metabolically active agent, unlike the very small (tracer) concentrations used in FDG-PET for example. As such, it is a completely different type of imaging which has only some type of relation with molecular imaging. I would rather consider GlucoCEST as a physiological or metabolic imaging technique, not a molecular one.

**O.I: What is the Gold Standard you can compare GlucoCEST with?**

**X.G:** The only existing Gold Standard is FDG (Fluorodeoxyglucose). FDG reports on two different processes: the glucose transport, and the hexokinase activity which is the first step in the glycolytic pathway. There are still interesting debates going on, on whether GlucoCEST can actually show any intracellular component or not. In normal tissue, generally, the sugar levels intracellularly never reach an amount that is high enough to be detected. Therefore, in normal tissue, it is unlikely that you would actually be able to use this method for intracellular glucose concentration. That might be

completely different for certain types of tumors, in which over-expression of both glucose metabolism as well as hexokinase activity actually leads to much faster metabolism. But this much faster metabolism, in which the starting component – glucose – is rapidly increased due to the overexpression of the glucose transporters, can only take place if the general level of glucose intracellularly is elevated; it just comes from the conservation of mass, a relatively simple physical law.

“

We are collaborating with Olea Medical® on looking specifically at what would be feasible from an image processing point of view to separate glucose delivery, transport and metabolism.

”

In my point of view, we should be able, in our case, at least in certain tumors, to get some readout about intracellular glucose metabolism.

How much? It is going to be an interesting question. We are collaborating with Olea Medical® on looking specifically at what would be feasible from an image processing point of view to separate glucose delivery, transport and metabolism. It is an open-ended question at this stage to know how much of these three different steps our method will be able to separate.

**O.I: How far have you tested it to date? Is there already a possibility for a clinical use or is it too early?**

**X.G:** We have tested these methods in several animal models so far, for cancer both in the brain and outside the brain. Other groups like Peter van Zijl's published very similar articles on models of breast cancer in mice, while some have worked on different cancer types in mice. Hence, this has been reproduced in at least 3 or 4 groups around the world. We are therefore pretty sure this is reproducible in experimental animal studies, and this is very important.

Talking about humans, we haven't published anything yet, due to some ethics requirements that delayed the start of the experiments; but at this stage, we are recruiting patients and gathering the first experience. In the meantime, there has been 2 different papers published on GlucoCEST in brain tumors at 7T: one by the Johns Hopkins group, one by the Deutsche Krebs Center in Heidelberg, Germany. An additional paper has also reported early experimental evidence of glucose uptake in Head and Neck cancer patients at 3T.

These are the early days, and almost all these papers didn't do anything else than showing that they could get a signal; it is a technical demonstration. However, what does this signal mean? Many questions arise; from the physiological point of view, is the signal coming from an intracellular compartment, or an extracellular one? Does the signal report on the perfusion which is the delivery, or the transport, or the metabolism, or all three? Maybe, maybe not, it is likely to be different in brain cancers and in solid body cancers. The brain has always been a bit different, it is the only organ in which FDG is not used because the entire brain itself is very glucose hungry.

Therefore, its contrast to noise ratio is not expected to be very high, at least if GlucoCEST reports on something similar to FDG. However, in some of the early demonstrations, it seems that the signal is slightly different from FDG; it might hence mean something else. How much of it is truly and only perfusion, how much of it is related to some form of metabolism or another? We don't know yet and there is a huge amount of effort to be done in that area. That is where we are from the clinical point of view: early days but promising.

**O.I:** Which applications for GlucoCEST Imaging do you expect in the near future? Do you believe that it could in some cases replace Gd MR enhancement methods?

**X.G:** It is clear at this stage that the main application would be for cancer. Is this ever going to become a whole-body technique? I would not think so. Nevertheless, as too many people said that MRI could not do this or that, I wouldn't say totally no. If we want MRI to detect metastases, we can use other methods such as whole body diffusion-weighted imaging, and this will detect

them. The problem is that it generates a lot of false positive; so we could actually focus on the most obvious sites with GlucoCEST to ensure that we have a direct readout on the metabolic activity of the tissue; that would be a possibility.

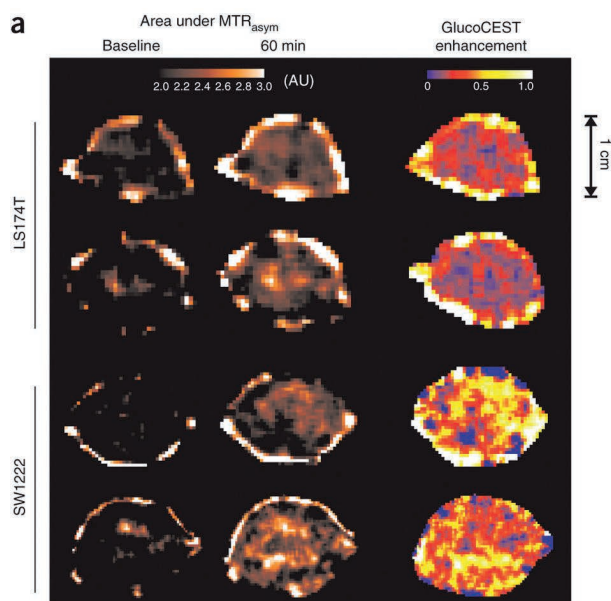
Also, the near future is going to be based on the results of our Horizon 2020 sponsored GLINT project, which is actually aiming at achieving two goals. On one side, demonstrating the possibility to use GlucoCEST in 3 types of patients: H&N carcinoma; lymphoma – particularly children lymphomas, because these patients generally require longitudinal studies and follow-up all their life, and it is absolutely key for the reduction of the amount of radiation; and gliomas. Here again, glioma is a rare disease but it is also the only cancer in which treatment hasn't changed much in the last 20 years; so there is an urgent need here in developing both biomarkers and different types of assessment. These are the main aims on the clinical side of the GLINT project.

“

... the near future is going to be based on the results of our Horizon 2020 sponsored GLINT project ...

”

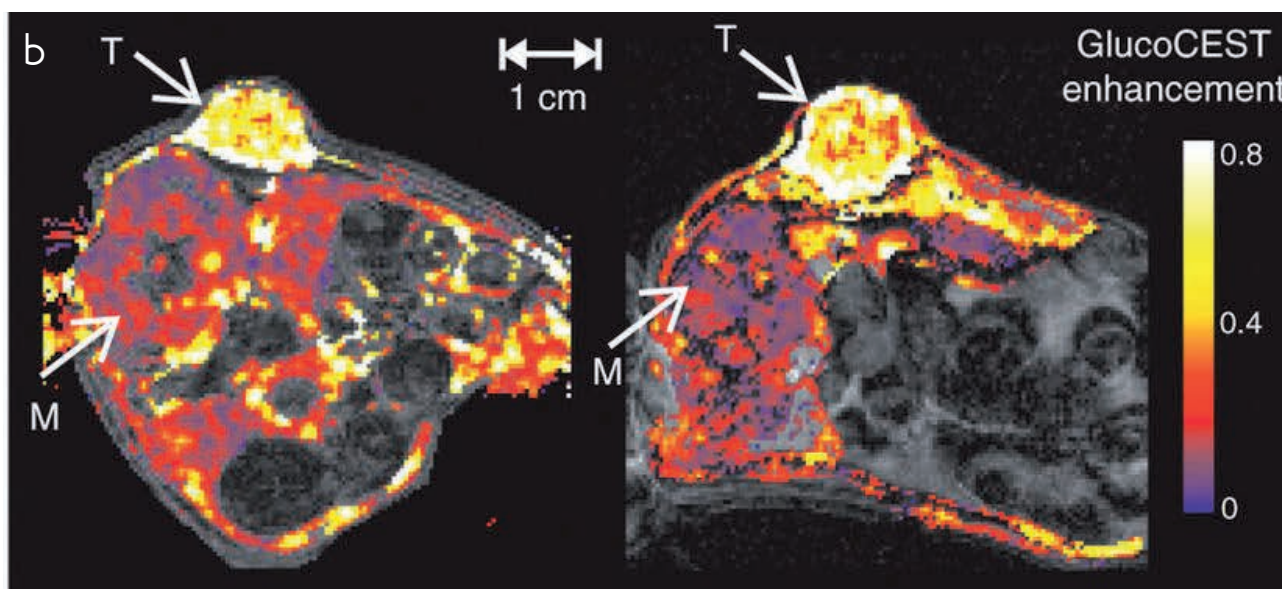
Now, on the pre-clinical side, we aim to bring forward the use of a particular glucose analogue called 3-O-methyl glucose (3OMG), a methylated glucose in the third position of the carbon. 3OMG has one advantage: upon injection, 99.99% of this glucose is excreted unmetabolized. In other words, this is an agent that can be injected, that can be transported by glucose transporters, however, it is not recognized by any of the key glycolytic enzymes such as hexokinase; therefore, it does not undergo any metabolism. It gets transported in and out of the cells, and then gets excreted. 3OMG has therefore, from a starting point of view, a very good safety profile. It is also a molecule for which one member of the consortium has a patent, which might actually allow one of our partner in this project, the Bracco pharmaceutical company,



**Figure 1:** *In vivo* glucoCEST data from subcutaneous tumor xenograft models.

(a) Example glucoCEST image data from four tumors showing the raw area under the magnetization transfer asymmetry ratios (MTR<sub>asy</sub>) images before and 60 min after injection of 1.1 mmol per kg body weight glucose solution. Images from two types of human colorectal tumor xenograft models with differing vascular and cellular phenotypes (LS174T and SW1222) are shown. The baseline image contrast reflects variations in water content, endogenous exchangeable protons, lipid signal and conventional magnetization transfer effects. Also shown are the corresponding GCE images, which show the change in MTR<sub>asy</sub> at 60 min after glucose injection. AU, arbitrary units.

(b) GlucoCEST enhancement (GCE) maps from a cross-section through two mouse xenografts, with arrows pointing to the tumor (T) and paraspinal muscle (M) regions. The color scale represents the amount of GCE, and the underlying grayscale images are for anatomical reference; regions subject to motion during the acquisition (for example, the gut) have been removed from the glucose images for clarity. Glucose uptake in the tumor is visibly higher than in the muscle. All data were acquired using the GE-CEST sequence. [1]



to get on with the development of that agent as a contrast agent. So this is one, the first one, of the potential new contrast agent based on this method. We might have some other interesting molecules developed during this project to be used as additional contrast agents.

The final idea is that we could imagine a particular examination where we would successively inject, maybe even in two different days, first a bolus of native glucose, and second the 3OMG – after waiting in the afternoon for blood glucose recovery. Imaging would then be done with an agent that gets delivered, transported, metabolized, versus one that gets delivered, transported but not metabolized. By making a difference between the two, we could potentially infer on the true glycolytic

rates of cancers. That would probably be one of the most amazing biomarkers that we could get, in terms of early response to therapy or in general about how metabolically active that particular cancer can be.

The potential is huge, once again we are at the early days, and there are years and years of research and development in that field. The applications are numerous, and they are all related to an increase in metabolism.

1. Walker-Samuel S, Ramasawmy R, Torrealdea F, Rega M, Rajkumar V, Johnson SP, Richardson S, Gonçalves M, Parkes HG, Årstad E, Thomas DL, Pedley RB, Lythgoe MF, Golay X. *In vivo* imaging of glucose uptake and metabolism in tumors. *Nature medicine*. 2013;19(8):1067-1072.

Interview by Sophie Campana Tremblay



# Innovation Partners

Our commitment to continuously help research and bring innovation to a broad scope relies on strong and ambitious partnerships



GLINT project will bring to the clinics a groundbreaking new technology which allows for more accurate, more reliable and earlier cancer diagnosis.

To learn more about this project  
**[www.glint-project.eu](http://www.glint-project.eu)**



The goal of this joint research program between hospitals and universities is to develop a new innovative platform to post-process cerebral and cardiac MRI sequences ischemic stroke and acute myocardial infarction.

To learn more about this project  
**[www.rhu-marvelous.fr](http://www.rhu-marvelous.fr)**



Improved diagnosis for life™

## fMRI: Imaging Brain Activity



Functional magnetic resonance imaging (fMRI) is a functional neuroimaging technique allowing the measurement of brain activity by detecting the changes in blood oxygenation and blood flow [1].

This approach relies on the fact that when a brain area is in use, the oxygen uptake increases.

To meet this demand, the local (hemodynamic) response is a blood flow rise in that region with increased neural activity [2]. Oxygen is delivered to neurons by hemoglobin in capillary red blood cells, and hemoglobin is diamagnetic when oxygenated but paramagnetic when deoxygenated. As a consequence, the changes in magnetic properties lead to small differences in the MR signal of blood, depending on the degree of oxygenation. These differences can be used to detect brain activity: it is called BOLD (Blood Oxygenation Level Dependent) effect, discovered by Ogawa et al. [3] in 1990.

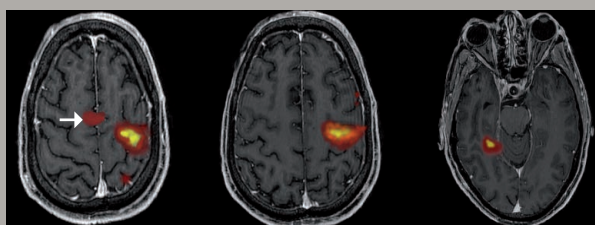
In order to assess the variations in blood oxygenation, paradigms with stimuli or events are requested to activate different parts of the brain; they must be synchronized with fMRI acquisition. Thus, during the acquisition with a T2\*-weighted gradient-echo echo planar imaging (EPI) sequence, the patient is asked to perform different tasks (for example, semantic word generation task based on short sentence processing for language areas, or finger tapping tasks for the motor areas) or can be stimulated to induce different processes or emotions. Many software packages are available for designing fMRI paradigms using earphones, screen or response button to stimulate and get feedback from the patient [4].

After a pre-processing step (including slice timing and motion correction, background segmentation, co-registration with anatomical series, spatial smoothing), the advanced statistical method GLM (General Linear Model) is often used to identify the voxels in which the signal varies according to the paradigm [5].

The GLM relies on the following equation:  $Y = X\beta + \varepsilon$

Where: Y is the BOLD response sampled in volumes; X is a known predictor variable (e.g. the onset and offset of an experimental condition);  $\beta$  is a scaling parameter;  $\varepsilon$  is the error.

fMRI activation maps, able to show which parts of the brain are involved in a particular mental process, are computed and color-coded depending on the strength of activation. Next, they are thresholded to be overlaid on anatomical series (Figure 1).



**Figure 1:** BOLD-fMRI activation maps from right-sided finger tapping task. The contralateral (left-side) primary sensorimotor cortex is more strongly activated. Note bilateral activation of the supplementary motor area (white arrow) and ipsilateral superior cerebellum (right image).

## Medical application

fMRI is being applied to patient care in several specialties including clinical neurology, neuroradiology, neurosurgery, neuropsychology, psychiatry and rehabilitation. In clinical practice, fMRI is mainly used for surgical or radiation therapy planning to analyze the localization of critical functions such as language or sensory-motor function, and to assess how risky the surgery (e.g. brain tumors, epilepsy) or the treatment is for the patient [6]. Mapping of functional areas is also useful to follow-up functional rehabilitation after neurological disorders: identification of the brain mechanisms governing recovery of function from stroke and head trauma, detection of early brain changes in neurodegenerative conditions like Alzheimer's disease, measurement of the psychoactive medications effects on neuro-developmental disorders, assessment of the degree of consciousness of patients in coma or vegetative state [1,6].

## Resting state fMRI

However, patients with brain pathologies can encounter difficulties in performing task-based paradigms. An interesting alternative is resting-state fMRI. This emerging technique consists in measuring brain activity when the patient is not performing any explicit task. Its initial purpose was to isolate physiological noise in fMRI data; but Biswal et al. [7] discovered that focusing on spontaneous low frequency fluctuations ( $<0.1\text{Hz}$ ) in the BOLD signal could allow to investigate the functional architecture of the brain, by mapping out its intrinsic connectivity networks (ICNs).

Measures of resting state fMRI appear to be stable; the ICNs observed in brain at rest show significant overlap with task-based activations, structural connectivity and maps of anatomical connectivity derived using retrograde tracers in macaques [8]. However, performing a specific task or factors such as current conscious, cognitive or emotional state have been shown to modulate functional connectivity within ICNs [8]. Therefore, the accuracy of resting state measures has been examined, and studies suggest that ICNs can be reliably detected across imaging sessions and subjects [8,9]. Clinical applications of resting-state fMRI are similar to standard fMRI but they are still at an early stage of development [9].

Brianna Bucciarelli

1. Huettel SA, Song AW, McCarthy G. Functional Magnetic Resonance Imaging. 2nd edition. 2009. Sinauer Associates Inc. Sunderland, MA. ISBN: 978-0-87893-286-3.
2. Logothetis NK, Pauls J, Augath M, Trinath T, Oeltermann A. Neurophysiological investigation of the basis of the fMRI signal. Nature. 2001 Jul 12; 412(6843):150-7.
3. Ogawa S, Lee TM, Kay AR, Tank DW. Brain magnetic resonance imaging with contrast dependent on blood oxygenation. Proc Natl Acad Sci USA. 1990

- Dec;87(24):9868-72.
4. James JS, Rajesh P, Chandran AV, Kesavadas C. fMRI paradigm designing and post-processing tools. Indian J Radiol Imaging. 2014 Jan;24(1):13-21.
5. Worsley KJ, Friston KJ. Analysis of fMRI time-series revisited-again. Neuroimage. 1995 Sep; 2(3):173-81.
6. Orringer D, Vago DR, Golby AJ. Clinical Applications and Future Directions of Functional MRI. Semin Neurol. 2012 Sep;32(4):466-75.
7. Biswal B, Yetkin FZ, Haughton VM, Hyde JS. Functional connectivity in the motor cortex of resting

- human brain using echo-planar MRI. Magn Reson Med. 1995 Oct;34(4):537-41.
8. Shehzad Z, Kelly AM, Reiss PT, Gee DG, Gotimer K, Uddin LQ, Lee SH, Margulies DS, Roy AK, Biswal BB, Petkova E, Castellanos FX, Milham MP. The resting brain: unconstrained yet reliable. Cereb Cortex. 2009 Oct;19(10):2209-29.
9. Lee MH, Smyser CD, Shimony JS. Resting state fMRI: A review of methods and clinical applications. AJNR Am J Neuroradiol. 2013 Oct;34(10):1866-72.



# Functional MRI & Resting state fMRI



**Andrei Holodny, MD**

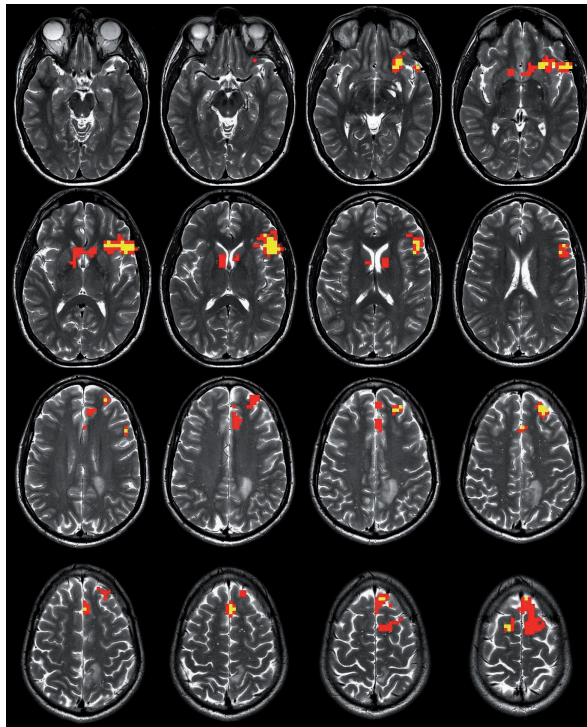
*Chief of Neuroradiology and Director of functional MRI laboratory at Memorial Sloan Kettering Cancer Center (MSKCC) in New York, NY, USA. Founding President of the American Society of Functional Neuroradiology.*

After completing his radiology residency and neuroradiology fellowship at New York University (NY, USA), Andrei Holodny was a fellow in experimental radiology at The National Hospital, Rikshospital in Oslo, Norway. Since 2001, he works at MSKCC.

Andrei Holodny is a member of the Editorial Board of the American Journal of Neuroradiology. He is the principle investigator on 3 active grants from the NIH (National Institutes of Health) and is the author of 140 peer-reviewed publications. He has a long-standing interest in functional MR imaging. He wishes to encourage and facilitate the introduction of functional neuroradiology into clinical practice.

**Olea Imagein:** Could you please briefly describe to our readers the principles and physiological basis of functional MRI, dependent on blood oxygenation level?

**Andrei Holodny:** I expect forgiveness from any physicist, but let's say I am at a cocktail party with a non-scientist, or with my parents or children, and I want to explain what I do with functional MRI and what it is all about; so I will give here an explanation for the non-scientists. Everybody knows that, what we are looking at in BOLD fMRI, is not neuronal activity; rather, we look at the changes in the blood flow that goes along with the neuronal activity. What happens in the brain when I start moving the finger in my left hand? The part of the brain that controls the movement of my finger in my left hand gives more blood to it. If I start using my muscles, more blood goes to them; if I start digesting food, more blood goes to my gut. Since we focus on the blood flow, we had to find a way to be able to look at it using fMRI. Everybody, even the non-scientists, understands that blood has hemoglobin in it, which contains a little iron. Everybody also knows that iron is a little magnet;



**Figure 1:** Resting state fMRI demonstrates the location of Broca's area and language Supplementary Area (pre-SMA) in patient with a left sided glioma. Courtesy of Wells Andres.

so, if there are many of these magnets flowing to a certain area of the brain, I can use my Magnetic Resonance Imaging scanner to find these differences. Again, I beg forgiveness for any physicist who is reading this, obviously this is a way to oversimplify the explanation.

“

In my belief, fMRI is absolutely necessary in glioma surgery.

”

**O.I:** Do you believe in the potential of fMRI-guided neurosurgery? What are the main limitations?

**A.H:** In my belief, fMRI is absolutely necessary in glioma surgery. This is supported first of all by the literature, secondly by neurosurgeons who are probably our most important support; but also by governmental organizations because now, the United States government pays for these procedures, which means they believe in this also. This has moved 15 years ago; when I started, fMRI was basically in higher academic institutions, but now it has moved into smaller private practice institutions. For example, I run a small fMRI course three times a year – that sells out three times a year – and approximately 75% of the people who attend this course are in private practice, not in high academic institutions; lots of them are pushed by their neurosurgeons to take this course.

The limitations of fMRI arise from the fact that it is sometimes difficult for the patient to actually perform the language paradigms. A lot of basic science fMRI work is done on normal graduate students who can perform these complicated paradigms in the MRI scanner and a lot of our patients are just not like that. They are older folks, they are people who have neurological problems, they are people who forget, who get confused in the scanner, and this is probably the main drawback in functional MRI.

**O.I:** What about resting state fMRI?

**A.H:** The reason mentioned before is precisely why resting state fMRI, which is a new technique, is really becoming a very interesting proposition. During paradigms designed for fMRI, where for example a



patient is asked to think about words starting with the letter 'N', the patient sits there and think about words starting with the letter 'N'. For somebody who is older and forgetful, this could obviously become a problem. In resting state fMRI, the advantage is that the patient does not have to do anything, he just lies in the scanner. Then using our advanced MRI techniques, we are able to, at least hopefully, extract all the information related to important areas in the brain, for example the motor cortex or the language cortex, which are essential in neurosurgery. A lot of work has been done on this technique by our group and other groups; for example the Washington University in Saint Louis has a wonderful group, the Harvard hospital and John Hopkins have great groups also. These are some of the advantages that hopefully will turn into real clinical move from resting state fMRI.

“ In resting state fMRI, the advantage is that the patient does not have to do anything, he just lies in the scanner. ”

There is another advantage, and this is where I really think resting state fMRI will come into fruition. First of all, there is really no question that task-based fMRI is important in neurosurgery for brain tumors. But not that many people get brain tumors, they mostly have neuropsychiatric disorders, whether Alzheimer's disease or Parkinson's disease or ADHD (Attention Deficit Hyperactivity Disorder) or autism or obsessive-compulsive disorder or anxiety, etc. This is where I think resting state fMRI will really come into fruition. From my clinical point of view, it is very difficult to tease these entities apart. Psychiatry used to be a question the doctor asks the patient: "how do you feel about this?". Right now, psychiatry is really moving towards much more quantitative or biomarker-types of analysis, which are based on MRI scan of the brain including resting state fMRI. The new head of the psychiatry institute at the NIH (National Institute of Health) is a quantitative person, I think that this is where things are going.

Another important thing is big data, because a number of interesting initiatives both in Europe and United States try to gather large amounts of scans to figure out what is the difference in, let's say, resting state connectivity or white matter connectivity between normal aging individuals and patients who have Alzheimer's disease. Once we are able to figure that out, we will be able to have templates to which we will compare patients, in order to see which groups they belong to.

**O.I: What are the hopes and promises for functional characterization of brain disorders using fMRI?**

**A.H:** The important thing is that this is a powerful new technique that allows us to see what parts of the brain are connected to what other parts of the brain. Let's take language for example. It used to be that people thought of two important language areas: Broca's area, which is in the inferior lateral aspect of the left ventricular lobe; and Wernicke's area, which is generally centered in the posterior aspect of the left superior temporal gyrus. People used to think about nodes in the brain, but now they consider this much more like a network of many different areas in the brain that connect to each other and will call the function of something like language.

This kind of connectivity between different parts of the brain seems to be disrupted in a lot of disorders, for example Alzheimer's disease or ADHD. A lot of the work right now has been focused on how there is a dysfunction in the connectivity, or on how one part of the brain connects to the other in different disorders. What is very interesting here is that there is lots of basic science done in papers in Nature or Science, but a lot of the staff is moving into the clinical area. For example, there are very interesting papers on connectivity in Parkinson's disease in Radiology, which is the clinical radiology journal. Therefore, the field is moving from basic science into the clinical area, which will hopefully be able to figure these things out and actually help our patients.

One of the stumbling blocks here is that there is really no well-defined method to analyze the resting state fMRI data. There are numbers of fundamentally different approaches to analyze them. For example, you can use a region of interest analysis, you can use graph theory, you can use independent moment analysis or principal component analysis. These are fundamentally different ways to look at the data.



Now what I really hope, and this is hopefully what Olea Medical® and other companies like you will be able to set into the flow front, is that the radiologist at his office will be able to analyze the data and come up with a helpful clinical report. Because right now, I have a whole bunch of physicists in my lab who can implement all these high techniques, so that I can look at these data as a scientist does, but not really as a clinician. So, this is another stumbling block towards applying these techniques to the clinical scenario. If companies which are in the high-end of analysis of data are moving high-end in neuroscience data towards the clinic, we should step up into this world.

**O.I:** What is your opinion about combining fMRI with other techniques, such as ASL, DTI, EEG or PET?

**A.H:** One of the most interesting things is to combine fMRI with diffusion tractography. Diffusion tractography, for the non-specialists, describes where the connections between one part of the brain and the other part of the brain are. Let's use for example a highway analogy. Diffusion tractography looks if there is a highway connection between one part of the brain and the other, whereas resting state fMRI looks at the traffic along this highway. Therefore, using this kind of car analogy, you can have a large highway but not that much traffic along it, or you can have a little road with a lot of traffic. This is definitely very interesting.

Also, what is very interesting is to understand how these things change over time, how the brain responds to various injuries, whether this is stroke or Alzheimer's disease or brain tumors – which is my area of interest. Some parts of the brain can respond very quickly and very well to injuries. For example like the skin: if you cut your skin, in a week it is back to completely normal. The brain is much worse at responding to injuries, but it is not zero. There is a very interesting French neurosurgeon, whose name is Hugues Duffau, who is actually a very big proponent of cortical reorganization in brain tumors. A lot of work like this, about DTI or functional MRI or MEG, which is a very interesting and powerful new technology, will allow us to attack these very important clinical questions.

**O.I:** Which future developments do you expect to increase both pathological sensitivity and specificity of functional MRI?

**A.H:** fMRI is essentially important in brain tumors. But now, we are in the clinical arena for diseases which are much more prevalent in Europe or the United States, like Alzheimer's disease or obsessive-compulsive disorders or depression. These are the diseases that resting state fMRI will be able to quantify.

“

Alzheimer's disease or obsessive-compulsive disorders or depression: these are the diseases that resting state fMRI will be able to quantify.

”

So, what will hopefully happen – and there is actually work on this – is to use different resting state fMRI patterns to identify certain patients which will be more susceptible to different treatments. This is a really wonderful step in the right direction, because if you can identify subsets – for example subset A, patients have connectivity between this part of the brain and that part of the brain, maybe they will respond to this kind of medication and will not respond to some other medication. This is a really interesting move forward which we were not really able to do before.

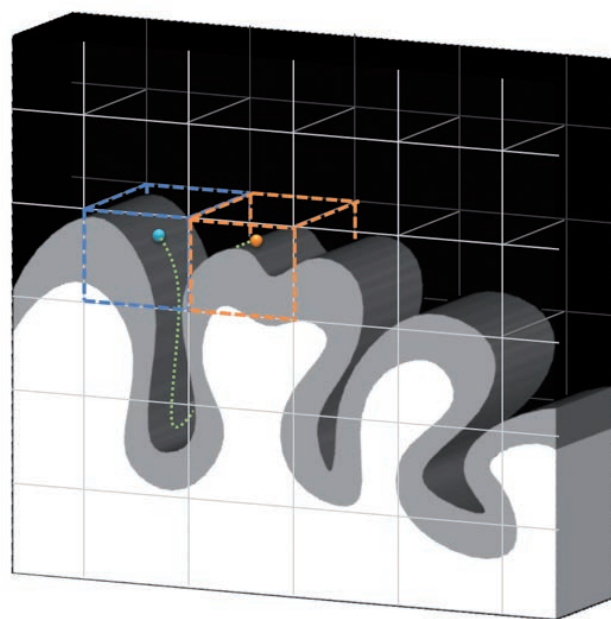
Interview by Brianna Bucciarelli

# An Inverse Surface-based Approach for Cortical fMRI Data Projection

Lucie Thiébaud Lonjaret

Functional magnetic resonance imaging (fMRI) is conceptually different from structural MRI as the patient is asked to achieve a specific task while being scanned. Indeed, neural activity induces local variations of deoxyhemoglobin ratio in the blood, thus changing locally the MRI signal strength because of deoxyhemoglobin paramagnetic properties, and thus giving rise to the Blood Oxygen Level Dependent (BOLD) signal measured in fMRI.

Usually, fMRI data are post-processed and analyzed in their acquisition space with voxel-based methods. Nevertheless, these techniques suffer from a major drawback: they do not take into account the anatomical characteristics of the brain, which results in them mixing signals that should never have been mixed together (Figure 1). Indeed the poor contrast to noise ratio in fMRI data imposes a denoising step which consists in filtering the data with a low-pass filter. Yet this step will induce some kind of averaging of the voxels' data on their direct neighborhood. However, the neighborhood defined on the voxels' grid does not follow the highly convoluted structure of the cortex. Methods based on the cortical surface exactly attempt to overcome this limitation by following the cortical geometry.



**Figure 1:** Voxel-based methods problem. On this voxels' grid, there are voxels mixing the signals coming from each side of the sulcus. Moreover, in the geodesic domain (i.e. along the cortical surface) signals are way more distinguishable from one another, as to go from one point on the left side (in blue) of a sulcus to the one on the right side (in orange) the green dots path has to be followed, whereas in the voxels' space those points belong to adjacent voxels.

Indeed, three points make it possible to assimilate the cortical ribbon to a surface in the framework of BOLD signals. First, the cortex is organized in functional units (called cortical columns) oriented orthogonally to its surface. Second, the cerebral micro blood vessels follow those columns overall. And third, the acquisition resolution (~3mm) is close to the cortical thickness.

A typical process followed by surface-based approaches consists in two main steps. First, they extract a mesh of the cortical surface from the anatomical volume segmentation in white matter (WM), grey matter (GM) and cerebro-spinal fluid (CSF). Any surface located in between the cortical ribbon boundaries (GM/CSF and GM/WM interfaces) can be considered. However, the inner one is usually preferred to the others as it offers good topological properties. Once this surface is reconstructed, the voxels' data are projected onto this mesh through interpolation techniques based on a more or less sophisticated weighting model.

The idea Olea Medical® is currently working on is another kind of surface-based approach which solves an inverse problem instead of simply interpolating the signal. Indeed, through the acquisition process by the fMRI scanner, the BOLD signal originating from the cortical grey matter is altered and, among others,

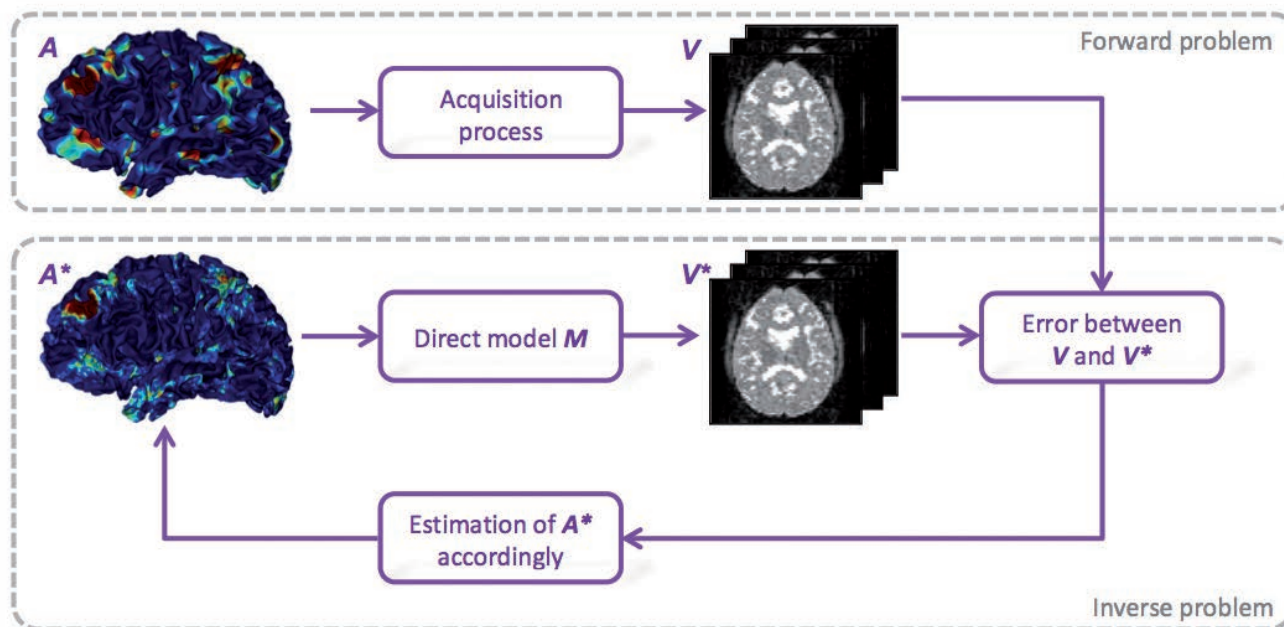
transposed onto a Cartesian voxel grid. With this new approach (aka. ISA), we virtually reverse this acquisition process (Figure 2) to restore the cortical BOLD signal free of any alteration.

Besides surface-based approaches offering a more relevant visualization space for brain fMRI, ISA will improve the estimation and detection of functional activations. This should lead to the spreading use of fMRI in the clinical context, especially by allowing resting state studies on individual subjects thanks to contrast to noise ratio improvement.

Thiébaud Lonjaret L, Bakhous C, Boutelier T, Takerkart S, Coulon O. ISA - an Inverse Surface-based Approach for cortical fMRI data projection. IEEE 14th International Symposium on Biomedical Imaging, ISBI 2017 (Melbourne, Australia).



**Lucie Thiébaud Lonjaret**  
Research Engineer  
Olea Medical®



**Figure 2:** Inverse surface-based approach. Whereas the forward problem consists in modeling the transformations induced by the acquisition process on the cortical hemodynamic response after a neuronal impulse, solving the inverse problem intends to reverse these transformations to retrieve the original signal  $A$  from the acquired data  $V$  and the forward model  $M$ .



## Synthetic MRI: Or how to play with contrast based on tissue properties

↓

Synthetic MRI is a Magnetic Resonance Imaging technique allowing to generate several post-acquisition contrast weighted images based on measurement of tissue properties – T1 longitudinal and T2 transverse relaxation times (and their inverses R1 and R2), and the proton density (PD); conversely, conventional MRI directly generates an image using the signal acquired from the tissue with only one contrast weighting per acquisition.

Two different approaches are today commercially available. The parametric maps quantifying the tissue parameters can be computed using either a particular MRI acquisition called QRAPMASTER (Quantification of Relaxation Times and Proton Density by Multiecho Acquisition of a Saturation-recovery using Turbo spin-Echo Readout) [1] or two standard acquisition sequences of T1 and T2 mapping – variable flip angle (VFA) or MP2RAGE for T1 mapping [2] and fast spin-echo (FSE) multi-echo for T2 mapping [3]. Olea Medical® chose the second option in its Olea Nova™+ plugin since these sequences are clinically relevant but also widely available on all MR scanners.

Using these parametric maps together with the signal equation of the type of computed image, different settings can be applied to create synthetic images, such as echo time (TE) and repetition time (TR) for a spin-echo (SE) sequence or TE, TR and inversion time (TI) for an inversion recovery (IR, FLAIR, STIR, PSIR) sequence.

A synthetic spin-echo image is obtained using the following equation (assuming 90° flip):

$$S = k \text{ PD } (1 - e^{-TR/T1}) e^{-TE/T2} \quad (1)$$

A synthetic inversion recovery image is obtained using the following equation (assuming 90° flip):

$$S = k \text{ PD } (1 - 2e^{-TI/T1} + e^{-TR/T1}) e^{-TE/T2} \quad (2)$$

Where S is the signal intensity in a pixel and k a proportionality constant which depends on the sensitivity of the signal detection circuitry on the imager [4].

1. Warntjes JB, Leinhard OD, West J, Lundberg P. Rapid magnetic resonance quantification on the brain: Optimization for clinical usage. *Magn Reson Med*. 2008 Aug;60(2):320-9.

2. Marques JP, Kober T, Krueger G, van der Zwaag W, Van de Moortele PF, Gruetter R. MP2RAGE, a self-bias-field corrected sequence for improved segmentation and T1-mapping at high field. *Neuroimage*. 2010 Jan 15;49(2):1271-81.

3. Oh J, Han ET, Pelletier D, Nelson SJ. Measurement of in vivo multi-component T2 relaxation times for brain tissue using multi-slice T2 prep at 1.5 and 3 T.

*Magn Reson Imaging*. 2006 Jan;24(1):33-43.

4. Bloch F. Nuclear induction. *Phys Rev* 1946;70:460-74.

5. Ortendahl DA, Hylton NM, Kaufman L, Crooks LE. Signal to noise in derived NMR images. *Magn Reson Med*. 1984 Sep;1(3):316-38.

6. Blystad I, Warntjes JB, Smedby O, Landtblom AM, Lundberg P, Larsson EM. Synthetic MRI of the brain in a clinical setting. *Acta Radiol*. 2012 Dec 1;53(10):1158-63.

7. Engström M, Warntjes JB, Tisell A, Landtblom AM, Lundberg P. Multi-parametric representation of

voxel-based quantitative magnetic resonance imaging. *PLoS One*. 2014 Nov 13;9(11):e111688.

8. Granberg T, Uppman M, Hashim F, Cananau C, Nordin LE, Shams S, Berglund J, Forslin Y, Aspelin P, Fredrikson S, Kristoffersen-Wiberg M. Clinical Feasibility of Synthetic MRI in Multiple Sclerosis: A Diagnostic and Volumetric Validation Study. *AJNR Am J Neuroradiol*. 2016 Jun;37(6):1023-9.

9. Hagiwara A, Hori M, Yokoyama K, Takemura MY, Andica C, Tabata T, Kamagata K, Suzuki M, Kumamaru KK, Nakazawa M, Takano N, Kawasaki H, Hamasaki N, Kunimatsu A, Aoki S. Synthetic MRI in the Detection

Producing different contrast weighted images from T1 and T2 parameters is an old concept (see Ortendahl et al., 1984 [5]) that gained interest for clinical practice only recently. In the early 2000s, these parameters could indeed be assessed in an acceptable acquisition time using new dedicated sequences. Therefore, the method attracted the interest of companies in the medical imaging field.

Synthetic MRI offers potential interesting clinical applications for brain diseases such as multiple sclerosis [6-9], brain metastasis [10], myelination patterns [11], Sturge-Weber Syndrome [12], but not only. This innovative technique has also been used in a post-mortem cardiac study related to myocardial infarct [13], or in musculoskeletal (MSK) disorders [14,15].

In addition to providing clinically useful information, the main advantage of Synthetic MRI is to offer flexibility. Creating a synthetic contrast weighted image is very quick and can be done after the patient has left the hospital. Synthetic MRI is a promising method that will be talked about for years to come.

*Note that it is important to check the impact of patient motion on Synthetic series computation and to be aware of the presence of potential artifacts on FLAIR contrasts.*

Brianna Bucciarelli

of Multiple Sclerosis Plaques. AJNR Am J Neuroradiol. 2017;38(2):257-63.

10. Hagiwara A, Hori M, Suzuki M, Andica C, Nakazawa M, Tsuruta K, Takano N, Sato S, Hamasaki N, Yoshida M, Kumamaru KK, Ohtomo K, Aoki S. Contrast-enhanced Synthetic MRI for the detection of brain metastases. Acta Radiol Open. 2016 Feb 15;5(2):2058460115626757.

11. Betts AM, Leach JL, Jones BV, Zhang B, Serai S. Brain imaging with synthetic MR in children: clinical quality assessment. Neuroradiology. 2016

Oct;58(10):1017-26.

12. Andica C, Hagiwara A, Nakazawa M, Tsuruta K, Takano N, Hori M, Suzuki H, Sugano H, Arai H, Aoki S. The Advantage of Synthetic MRI for the Visualization of Early White Matter Change in an Infant with Sturge-Weber Syndrome. Magn Reson Med Sci. 2016 Oct 11;15(4):347-8.

13. Schwendener N, Jackowski C, Persson A, Warntjes MJ, Schuster F, Riva F, Zech WD. Detection and differentiation of early acute and following age stages of myocardial infarction with quantitative

post-mortem cardiac 1.5T MR. Forensic Sci Int. 2017 Jan;270:248-54.

14. Delattre B, Vargas M, Boudabbous S. Feasibility of Synthetic MRI in knee in routine practice: image quality and diagnostic accuracy. ISMRM 2017 (Honolulu, HI, USA).

15. Lee YH. New horizon of fast MSK imaging: Clinical application in MSK Field. ICMRI 2017 (Seoul, Korea).



## Synthetic MRI

### **Kambiz Nael, MD**

*Associate Professor of Radiology in the Division of Neuroradiology at The Icahn School of Medicine, Mount Sinai, New York, NY, USA.*

Kambiz Nael is a board-certified radiologist with specialty certification in neuroradiology. Currently, he is an Associate Professor of Radiology and Director of Neuroradiology MRI, CT and Advanced Imaging at Icahn School of Medicine at Mount Sinai.

Kambiz Nael has over 100 scientific presentations and has authored or co-authored more than 60 scientific articles. His clinical and research interests include advanced neurovascular imaging and quantitative multiparametric neuroimaging approach in the diagnosis of a variety of cerebrovascular disorders and brain and spinal neoplasms.

Kambiz Nael is a senior member of the American Society of Neuroradiology (ASNR) and also holds membership in the Radiologic Society of North America (RSNA), International Society of Magnetic Resonance Imaging in Medicine (ISMRM), Western and Eastern Neuroradiology Society (WNRS and ENRS), American Society of Head and Neck Radiology (ASHNR), and American Heart Association, Stroke Council (AHA/ASA).



**Olea Imagein:** Over the past years, you focused on the potential use of Synthetic MRI approach for the diagnosis of cerebrovascular disorders. Could you please describe the reasons of your interest?

**Kambiz Nael:** I have always been interested in new MR technologies, and Synthetic MRI is no exception. As a neuroradiologist, I am obviously interested in applications that can advance the knowledge in my field. The idea of Synthetic MRI has been around for a long time, our Department Chair, Dr. Burton Drayer, has published one of the first paper on this topic several years ago.

“

The idea of getting not only qualitative but also quantitative data, I believe, is really the appealing part of Synthetic MRI.

”

When I was informed by Olea Medical® that a project was going on to develop a Synthetic MRI methodology, I was excited. The idea of getting not only qualitative but also quantitative data, I believe, is really the appealing part of Synthetic MRI.

**O.I:** What are the current limitations of Synthetic MR imaging? Are these limitations an impediment for a clinical use?

**K.N:** I believe that the major limitation currently is how to deal with and reduce the artifacts. Just focusing on Neuroradiology and brain MRI, we need multiplanar multisequential MR images for accurate evaluation of different brain pathologies. One of the most important sequences is FLAIR, which in my opinion suffers from significant artifact when computed from Synthetic MRI. Of course, there has been some improvement in quality of Synthetic FLAIR, by using multiple echo technique with more than 3 echoes. But the artifacts largely related to partial volume averaging still persist and can be misleading towards a wrong diagnosis in some instances.

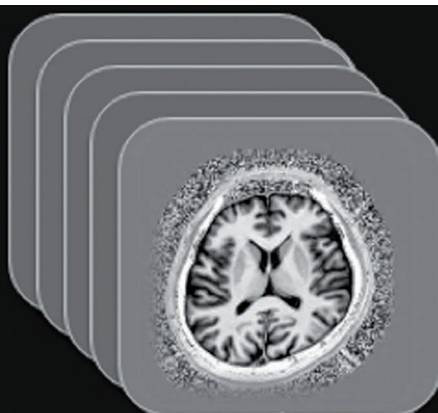
Some other limitations include lack of Gradient images (GRE) and diffusion imaging (DWI) from Synthetic module in its current state, these are sequences that must be included in a routine brain MRI. Therefore, these acquisitions still need to be made separately, and time saving promised by Synthetic MRI is in question.

**O.I:** How about the advantages of this approach compared to equivalent MRI series?

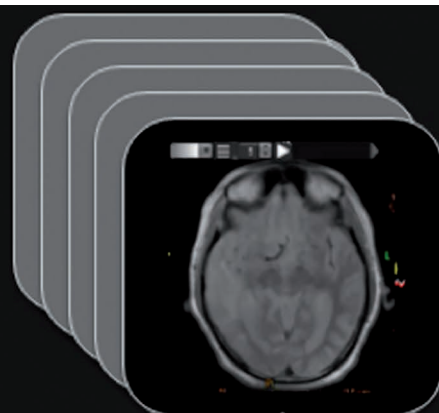
**K.N:** The main advantage of Synthetic MRI is to provide quantitative values: T1, T2, R1 and R2 maps, a potential advantage over the conventional MRI that can be used for further brain tissue characterization.

It will be beneficial if we can obtain and compute the Synthetic maps in 3D. The way we proceed with

**Figure 1:** Brain synthetic maps computed using Olea Nova™+ plugin obtained from both MP2RAGE and fast spin-echo (FSE) multi-echo sequences acquired on a Toshiba Medical's Vantage Galan™ 3T MR system.



MP2RAGE



Variable TE

Olea Sphere® is the following: the algorithm uses a combination of MP2RAGE and multi-echo T2 and then computes the 2D Synthetic maps; but, since MP2RAGE is a volumetric 3D acquisition, it would be ideal to obtain a volumetric T2 and find a way to reconstruct the Synthetic maps in 3D. This may be an application for sequential volumetric and lesion analysis in patients who received multiple scans such as brain tumor, multiple sclerosis and dementia, for whom we can assess the tissue and lesion signal and quantitative maps over time and identify measure of prognosis or treatment response.

“

I think Synthetic MRI provides added value to conventional imaging but may be not necessarily replacing it.

”

**O.I:** How promising could be Synthetic MRI? Do you believe that in the future this approach could replace equivalent conventional MRI series? Is there a question of confidence?

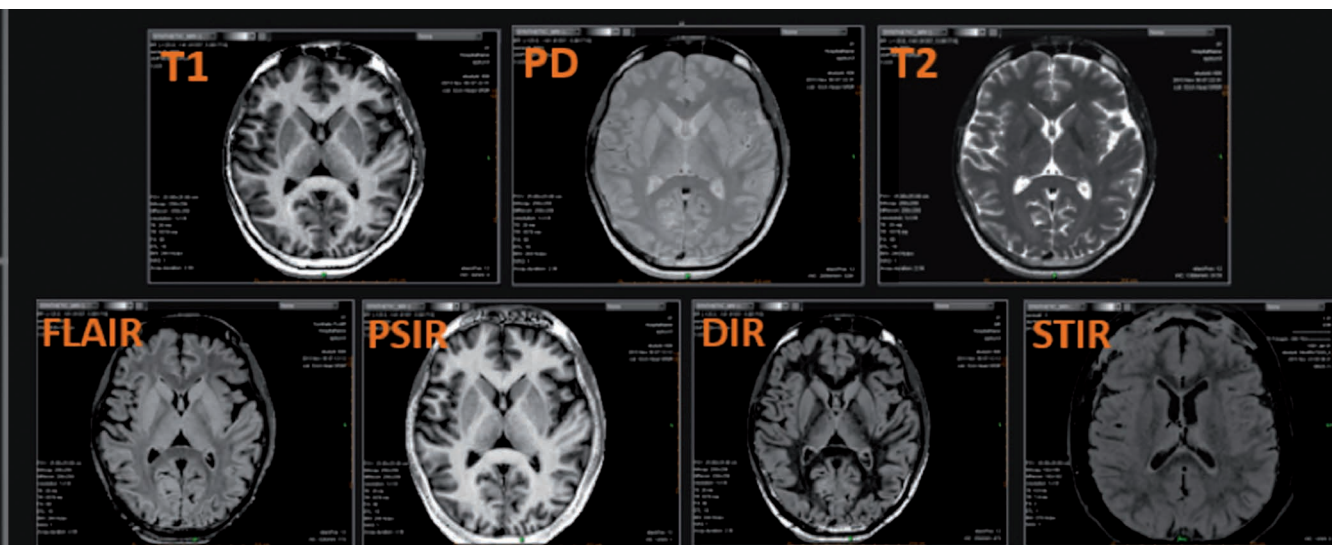
**K.N:** Trust comes with data of good quality. In order to boost the radiologist and clinician confidence; we need to improve the image quality with less artifacts. I will use a synthetic FLAIR that is comparable to conventional FLAIR in terms of image quality. In addition we need to figure out what to

do with missing sequences in the current Synthetic Brain MRI platform, i.e. diffusion and GRE? Without diffusion computing, Synthetic MRI cannot in its current state replace Conventional MRI; diffusion MRI is required for every brain scan to make sure we are not missing acute infarction. I think synthetic MRI may have added value to the conventional imaging but is not necessarily ready to replace it entirely. I also believe that in the future the major focus for Synthetic MRI should be shifted towards quantitative MRI to provide important complementary value to conventional MRI.

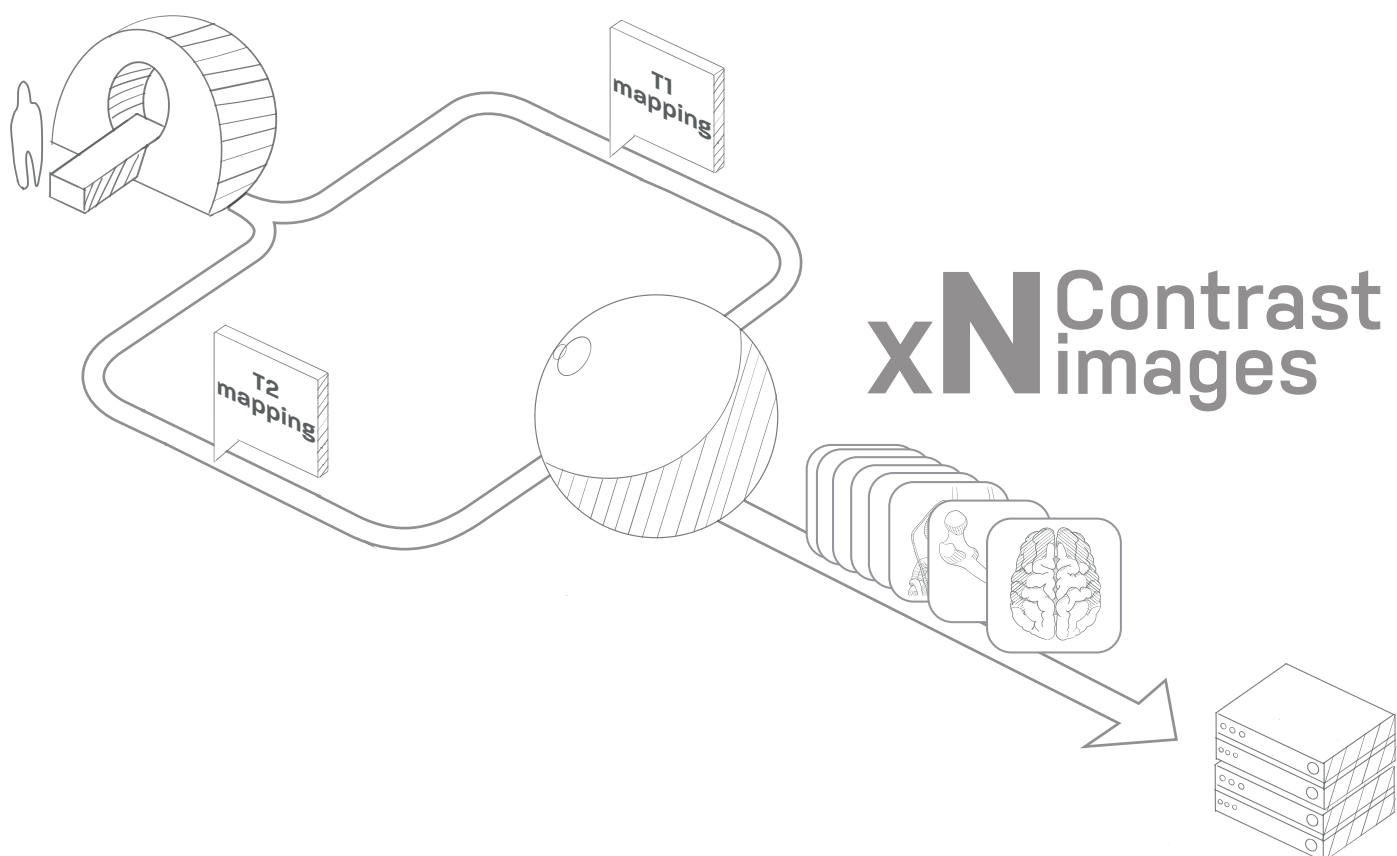
**O.I:** Another method, MR Fingerprinting, is yielding similar outcomes for quantitative MRI. How would you compare both techniques, in terms of pros and cons?

**K.N:** I do not have enough experience with MR Fingerprinting; but from a technical point of view, if you consider Synthetic MRI as a predominantly post-processing concept (at least from Olea Medical® perspective), MR Fingerprinting is a novel approach that involves not only post-processing but also data acquisition and visualization. In MR Fingerprinting, a pseudo-randomized acquisition is used that causes the signals from different tissues to have unique fingerprints, and pattern recognition is used for post-processing to match the fingerprints to a predefined dictionary of predicted signal evolutions. It is something we would like to get involved in, because though early, it is a very promising technique.

Interview by Sophie Campana Tremblay



Bring flexibility  
to your patient management



**Olea Nova<sup>TM</sup> + v1.0\***

CONVENTIONAL SEQUENCES. MULTIPLE CONTRASTS. ONE SOLUTION.

For more information: [www.olea-medical.com](http://www.olea-medical.com)

\*Olea Nova<sup>TM</sup> v1.0 is CE marked, indicated for head imaging, may be used for other organs for research only. Not FDA cleared.



Improved diagnosis for life<sup>TM</sup>



## Texture analysis: From methods to applications



Texture is a complex visual pattern composed of spatially organized, repeated subpatterns, whose properties can be lightness, uniformity, density, roughness, regularity, linearity, frequency, phase, directionality, coarseness, randomness, fineness, smoothness, granulation, etc. [1]. However, even though easily perceived by the human eye, there is no strict and satisfactory usual definition related to the notion of the texture.

Moreover, when trying to describe an image, the concept of texture becomes even more difficult. Russ [2] defined image texture as a descriptor of local brightness variation from pixel to pixel in a small neighborhood through an image. Texture can hence be described as an attribute representing the spatial arrangement of the grey levels of the pixels in a region of a digital image.

Texture analysis (TA) played a central role in medical imaging, satellite imaging, remote sensing etc., and its tasks are mainly synthesis, image classification and segmentation, so as to establish boundaries between regions [3, 4]. The approaches of texture analysis are mainly based on the method used for textural features extraction. Four basic methods are defined: (1) statistical, (2) structural, (3) model-based and (4) transform-based.



1. Levine M. Vision in Man and Machine, McGraw-Hill, 1985.
2. Russ JC. The Image Processing Handbook. 3rd edition, CRC Press, Florida, 1999.
3. Bharati MH, Liu JJ, MacGregor JF. Image texture analysis: methods and comparisons. Chemometrics and Intelligent Laboratory Systems, 2004;72(1):57-71.
4. Nailon WH. Texture analysis methods for medical image characterization. Chapter 4. In Biomedical Imaging, Mao Youxin, Editor. 2010.
5. Castellano G, Bonilha L, Li LM, Cendes F. Texture analysis of medical images. Clinical Radiology. 2004;59(12):1061-1069.
6. Haralick RM, Shanmugan K, Dinstein I. Textural Features for Image Classification. IEEE Transactions on Systems, Man and Cybernetics. 1973;3(6):610-621.
7. Waugh SA. The Use of Texture Analysis in Breast

- Magnetic Resonance Imaging. PhD Thesis. University of Dundee, UK. 2014.
8. Mitchell OR, Myers CR, Boyne W. A Max-Min Measure for Image Texture Analysis. IEEE Transactions on Computers. 1977;26(4):408-414.
9. Galloway MM. Texture analysis using gray level run lengths. Computer Graphics and Image Processing. 1975;4:172-179.
10. Kvaal K, Wold JP, Indahl UG, Baardseth P, Næs T. Multivariate feature extraction from textural images of bread. Chemom. Intell. Lab. Syst. 1998;42:141-158.
11. Materka A. Texture analysis methodologies for magnetic resonance imaging. Dialogues Clin Neurosci. 2004;6(2):243-50.
12. Gonzalez, RC, Woods RE. Digital Image Processing. Reading, Mass.: Addison-Wesley, 1992.
13. Haralick RM. Statistical and Structural Approaches

- to Texture. Proc. IEEE. 1979;67(5):786-804.
14. Serra J. Image Analysis and Mathematical Morphology. Academic Press, 1982.
15. Dougherty ER, Lotufo RA. Hands-on morphological image processing. Bellingham, WA: SPIE Press, 2003.
16. Carlucci L. A formal system for texture languages. Pattern Recognition. 1972;4(1):53-72.
17. Zhang J, Tan T. Brief review of invariant texture analysis methods. Pattern Recognition. 2002;35(3):735-747.
18. Hassner M, Sklansky J. The Use of Markov Random Fields as Models of Texture. Computer Graphics and Image Processing. 1980;12:357-370.
19. Derin H, Elliot H. Modeling and segmentation of noisy and textured images using Gibbs random fields. IEEE Transactions on Pattern and Machine

#### STATISTICAL(\*)

"This method is based on representations of texture using properties governing the distribution and relationships of grey-level values in the image" [5]

##### Main methods:

- Grey level co-occurrence matrix(\*\*) [6]
- Moments of grayscale histograms [5]
- Min-Max method [8]
- Run-length matrix [9]
- Absolute gradient method [5]
- Singular Value Decomposition (SVD) spectrum [10]

#### STRUCTURAL(\*\*\*)

"Describe a texture by well-defined primitives (micro-texture) and a hierarchy of spatial arrangements (macro-texture) of those primitives" [1, 13]

##### Main methods:

- Mathematical morphology [14, 15]
- Texture elements – primitives [16]

#### MODEL-BASED(+)

"A texture image is modeled as a probability model or as a linear combination of a set of basis functions. The coefficients of these models are used to characterize texture images" [17]

##### Main methods:

- Markov random fields [18]
- Gibbs random fields [19]
- Auto-regressive Model [20]
- Word-like Model [21]
- Fractal Model [22, 23]

#### TRANSFORM-BASED(++)

"Represent an image in a space whose coordinate system has an interpretation that is closely related to the characteristics of a texture" [5]

##### Main methods:

- Wavelet transform [24]
- Fourier transform [25]
- Gabor filters [26]

(\*) Statistical based methods are supposed to provide better discrimination between classes than transform-based or structural methods [5] and are the most widely used in medical applications [7].

(\*\*) Co-occurrence matrix, and its derived second order statistical features, is the most popular approach for texture analysis and has been demonstrated to allow an effective texture discrimination in biomedical images [11].

(\*\*\*) Practically, structural methods seem to be limited since they can only describe very regular textures [12] and are more useful for synthesis than analysis tasks [11].

(+) The main issue of the Model-based methods, is the computational complexity involved in the estimation of the related parameters [5].

(++) In this approach, the Wavelet transform is the most widely used method because of the ease with which it may be adjusted [5].

### Medical applications

Texture analysis has been widely used in the medical field. Nedelec et al. [27] demonstrated that TA could be useful in the diagnosis and monitoring of therapies for Alzheimer's disease. Zacharaki et al. [28] showed that TA applied to MRI images could allow glioma grading and differentiation between gliomas and metastases in brain, with concomitant sensitivity and specificity. Furthermore, TA has also been used to identify lesions and abnormalities that were not visually observed in epilepsy sufferers [29]. Regarding liver diseases studies, TA has been used for prediction of postoperative hepatic insufficiency [30]. Finally, TA was applied in the prediction of response to chemotherapy for breast cancer patients [31].

Yasmina Chaibi

Intelligence. 1987;9(1):39-55.

20. Jain A. Fundamentals of Digital Image Processing. Prentice-Hall International, Englewood Cliffs, 1989.

21. Liu F, Picard RW. Periodicity, directionality, and randomness: wold features of image and modeling and retrieval. IEEE Trans. Pattern Anal. Mach. Intell. 1996;18 (7):722-733.

22. Pentland AP. Fractal-based description of natural scenes. IEEE Trans Pattern Anal Mach Intell. 1984;6(6):661-74.

23. Sarkar N, Chaudhuri BB. An efficient approach to estimate fractal dimension of textural images. Pattern Recognition. 1992;25(9):1035-1041.

24. Lu C, Chung P, Chen C. Unsupervised Texture Segmentation via Wavelet Transform. Pattern Recognition. 1997;30(5):729-742.

25. Bracewell R. The Fourier transform and its applications, 3rd ed. McGraw-Hill: New York, 1999.

26. Bovik A, Clark M, Geisler W. Multichannel texture analysis using localized spatial filters. IEEE Trans. Pattern Anal. Mach. Intell. 1990;12(1):55-73.

27. Nedelec JF, Yu O, Chambron J, Macher JP. Texture analysis of the brain: from animal models to human applications. Dialogues Clin Neurosci. 2004;6(2):227-233.

28. Zacharaki EI, Wang S, Chawla S, Soo Yoo D, Wolf R, Melhem ER, Davatzikos C. Classification of brain tumor type and grade using MRI texture and shape in a machine learning scheme. Magn Reson Med. 2009;62(6): 1609-18.

29. Yu O, Mauss Y, Namer IJ, Chambron J. Existence of contralateral abnormalities revealed by texture

analysis in unilateral intractable hippocampal epilepsy. Magn Reson Imaging. 2001;19(10):1305-10.

30. Simpson AL, Adams LB, Allen PJ, D'Angelica MI, DeMatteo RP, Fong Y, Kingham TP, Leung U, Miga MI, Parada EP, Jarnagin WR, Do RK. Texture Analysis of Preoperative CT Images for prediction of postoperative hepatic insufficiency. J Am Coll Surgeons. 2015;220(3):339-346.

31. Ahmed A, Gibbs P, Pickles M, Turnbull L. Texture analysis in assessment and prediction of chemotherapy response in breast cancer. J Magn Reson Imaging. 2013;38(1): 89-101.



# MSK & Texture analysis



## **Ashley Williams, MS**

*Research and Development Scientist and Engineer, Department of Orthopaedic Surgery, Stanford University, Stanford, California, USA.*

After graduating from the University of Colorado, where she studied aerospace engineering and dance, and then from the Massachusetts Institute of Technology (MIT), where she did graduate work in bio-electric engineering, Ashley Williams started working with Dr. Constance Chu in the Cartilage Restoration Program in the Department of Orthopaedic Surgery at University of Pittsburgh (Pittsburgh, Pennsylvania, USA); and then in the Department of Orthopaedic Surgery at Stanford University (Stanford, California, USA). Her clinical research focuses on the diagnosis of osteoarthritis and joint degeneration in hopes of preventing injuries.



**Olea Imagein:** Could you please explain how texture analysis can add value to the information obtained from musculoskeletal (MSK) images?

**Ashley Williams:** In MSK imaging, T2 relaxation maps of articular cartilage contain a wealth of information about the biochemical and structural integrity of the tissue. While our eyes are pretty good at visually appreciating subtle differences in cartilage T2 spatial distributions due to injury or disease, capturing that information in a quantifiable way is non-trivial. Textural analyses of qMRI relaxation maps, like T2 and UTE-T2\*, permit quantifiable characterization of cartilage's healthy anisotropic laminar structure and can also provide objective measures of degenerative changes to that structure.

**O.I:** Do you believe texture analysis can help in the differentiation between healthy and pathological tissue in MSK application?

**A.W:** Yes, I believe that textural analysis has the potential to identify signs of reversible cartilage injury and degeneration – which is key to the development of effective osteoarthritis (OA) prevention and therapeutic strategies. My group, under the direction of Dr. Constance Chu at Stanford University, and others have shown that cartilage T2 texture features are sensitive to OA-induced changes to the articular cartilage matrix

organization. In addition, cartilage textural analyses can detect pre-clinical degenerative changes to cartilage anisotropy in subjects at elevated risk of developing OA.

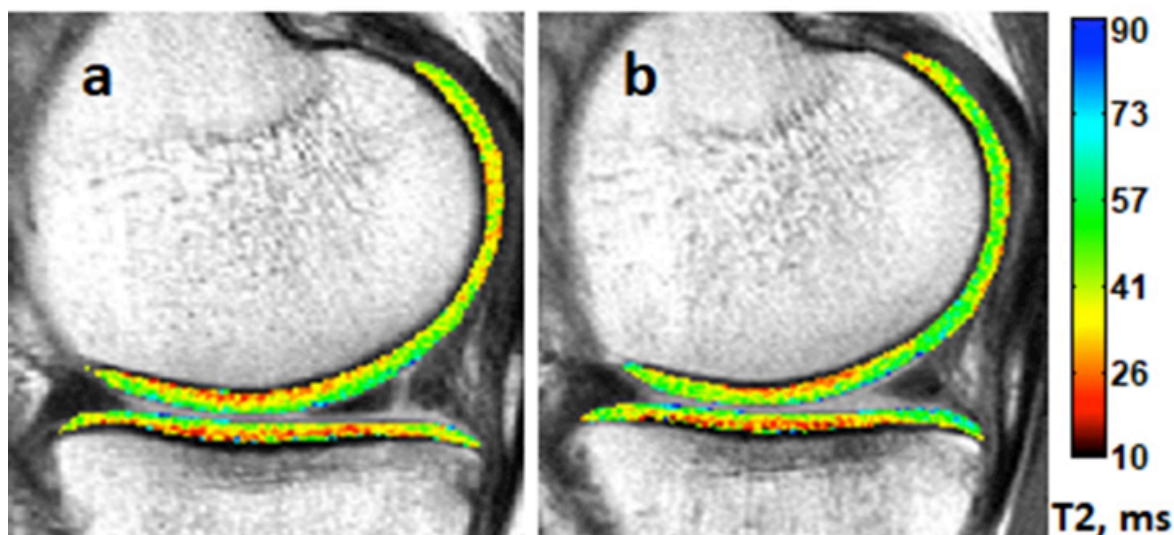
**O.I:** In the future, do you think the use of texture analysis will increase in MR imaging?

**A.W:** That will depend on how user-friendly texture analysis tools become. At the moment, specialized software is custom-coded by individual MSK research groups. Texture analysis is time and effort intensive, and has been limited to assessing cartilage regions that can be easily 'flattened', a necessary step for second-order texture measures to reflect laminar spatial organization. Further studies are needed to realize the full-potential of texture analysis – and better tools are needed to perform those studies.

**O.I:** Which new applications do you expect?

**A.W:** New hot topics in MSK research include bone-cartilage cross-talk, or the ability of subchondral bone health to influence articular cartilage health and vice-versa. Visualization of degenerative and healing processes in this complicated and short-T2 region is an area of active research, and an area that I expect may help shape the future MSK imaging.

Interview by Brianna Bucciarelli



**Figure 1:** Texture analysis permits quantitation of early changes of T2 distribution in knee articular cartilage following anterior cruciate ligament (ACL) reconstruction. Sample T2 maps acquired prior to (a) and 6 months after (b) ACL reconstruction surgery demonstrate subtle changes to the spatial distribution of T2 values over time while mean T2 values remain stable. Texture analysis permits quantitation of these early changes. T2 maps generated with MRImapper® software (Beth Israel Deaconess and MIT 2006). Figure courtesy of Dr. Constance R. Chu and Ashley Williams. For more information on this work, please see: Williams, et al. Early articular cartilage MRI T2 changes after anterior cruciate ligament reconstruction correlate with later changes in T2 and cartilage thickness. J Orthop Res. 2017 Mar;35(3):699-706.

# MSK & Sport in medicine



**Mario Padron, MD**

*Chairman of the Department of Radiology at Clinica Cemtro, Madrid, Spain.*

Mario Padron was Chief of the Musculoskeletal Section of the Department of Radiology at the University Hospital of La Princesa in Madrid between 1990 and 1994, and Medical Director of the MRI Center in Clinica San Camilo between 1992 and 1998. Since 1998, he is the Chairman of the Radiologic Department at Clinica Cemtro, Orthopedic Institute (Madrid, Spain).

Mario Padron is specialized in musculoskeletal imaging, sport medicine and orthopedic surgery, as an expert of the Spanish Olympic Committee and a senior consultant in imaging for the Spanish Royal Federation of Athletics and the Royal Spanish Federation of Football.

Founder and Vice-President of the Spanish Society of Skeletal Radiology in 1998, Mario Padron was the Chairman of the Subcommittee of Sports Imaging of the European Society of Skeletal Radiology (ESSR) between 2006 and 2009. He was President of the ESSR 2013. He has published and presented several papers, oral presentations, conferences and book chapters in both local and international journals and scientific meetings in Europe, North America and Asia.

**Olea Imagein:** Could you please describe to our readers the scope of your clinical practice, your research interests and the MR routine protocol for sport medicine?

**Mario Padron:** I am the Chairman of the Radiology Department at Clinica Cemtro in Madrid, Spain. This clinic is dedicated to sport traumatology and orthopedic surgery, with a particularly long experience in cartilage imaging. We are specialized not only in imaging of the cartilage but also in the pre- and post- cartilage transplantation care. Our clinic has a very important research area, where we normally do the culture of the cells. But we have also developed a model called Instant Cemtrocell®, meaning that a large amount of cells are cultured and harvested from the patient, before the reimplantation of these cultured cells inside his or her joint. Clinica Cemtro is one of the most experienced centers in the world dealing with this technique in cartilage surgery.

Many sportsmen come to the clinic every year with different types of issues. We usually do the diagnosis with MRI using these new sequences that we are developing, and we perform the surgery as well.

“

So, we are able to see pre- and post-operatively how the cartilage is working with both morphologically and biochemistry focused sequences.

”

**O.I:** MR imaging relates to the micro and macro structure of articular cartilage. What are the current MR applications for both diagnosis and surgical planning?

**M.P:** We use a mix of sequences to image the cartilage. One set of imaging series is dedicated to the morphological structure, so that we can delimitate the depth and the extension of the lesion; it is a morphological characterization. But there is another set of sequences that is performed to evaluate the function of the cartilage; it focuses on

biochemistry, or biochemical procedures that happen inside the cartilage. These advanced imaging sequences can be dGEMRIC (delayed Gadolinium Enhanced Magnetic Resonance Imaging of Cartilage) techniques, T2 mapping, T1rho, etc. They help knowing, for example, the content of collagen structure. So, we are able to see pre- and post-operatively how the cartilage is working with both morphologically and biochemistry focused sequences.

We are also working on another set of pulse sequences that are very accurate to define the deepest layer of the cartilage, where the chondrocytes are developing. We are able to see how deep the lesions are, if they are affecting this chondrogenic area, and this is very important to assess how the cartilage is working.

**O.I:** Regarding advanced quantitative imaging, do you believe that one day we will be able to assess the glycosaminoglycan content, or to provide a collagen metrics?

**M.P:** Yes, that is the aim of the type of sequences we are using. Regarding quantitative imaging, we are working in very close relationship with Olea Medical®, in order to evaluate the glycosaminoglycan (GAG) content. We can already estimate the relative amount of the proteoglycans or GAG via a color mapping. But we hope that, thanks to new developments and improvements of this type of techniques, we will be able to quantify the real amount of GAG, in order to assess what is happening in different areas of the cartilage. And, also, probably, there is some targeting to be done with the contrast agent that we introduced in the dGEMRIC technique, so that we can better characterize the cartilage.

**O.I:** What about gagCEST?

**M.P:** GagCEST is a new technique under development. But, in order to use it, we will probably need high field scanners, up to 7T. It is not approved for clinical use yet, therefore it is only for research. Nevertheless, it is another possibility to perform those biochemical quantifications of the cartilage.



**O.I: What do you think about specific, or combined, techniques such as PET-MRI, or UTE MRI?**

**M.P:** UTE or ultrashort echo time is amazing. We have been working on ultrashort TE for the past years. It is now one of the sequences that we use routinely for the characterization of cartilage post-operatively, in order to quantify the functionality of the deepest layer of the cartilage, the chondrogenic area. The maps that we generate with the Olea Sphere® software are all performed with UTE. This is a very useful development, because we can tell the surgeon when the cartilage becomes functional after the transplantation. Though still under research, we routinely use UTE and compare it with the normal T2 mapping.

PET-MRI is not adapted to the degenerative or trauma lesions of the cartilage, it is more directed into oncology, tumors and some metabolic diseases.

“

The main direction is, of course, biochemical imaging with biomarkers.

”

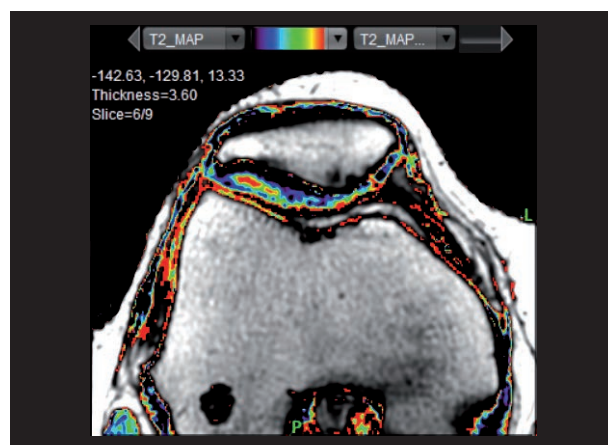
**O.I: What is still missing in your clinical practice routine, and what do you expect from musculoskeletal imaging in the future?**

**M.P:** Regarding musculoskeletal imaging, we are working together with several companies on the development of a single imaging modality that could integrate different ways of facing an orthopedic issue. For instance, we are working on a new imaging sequence called zero-echo time or ZTE. It is a promising modality that allows us to evaluate the cortical bone. This is amazing because we can mix this type of imaging with aspects that we see in the CT scan. However, the advantage is that with MRI we can not only evaluate the cortical bone, but also the medullary bone – very sensitive to MRI – and the soft tissues. Therefore, with one imaging modality,

we can have a good overview of the lesions of the medullary bone, cortical bone and surrounding soft tissues, including vessels and nerves.

Having a morphological approach of the problems in the joint, bone, soft tissue or skeleton is important. If we have a unique modality, we can, maybe, in the next future, avoid some irradiating X rays or CT-scan, and do everything with MRI.

Of course, another aim is functional imaging, which is going to develop very rapidly in the next years. I believe that the combination of morphological and anatomical features with biomarkers and biochemical processes that happen not only in the cartilage but also in the muscles or in other structures will provide a much better clinical approach. The main direction is, of course, biochemical imaging with biomarkers.



**Figure 1:** Thresholded T2 map obtained using Relaxometry plug-in in Olea Sphere® software fused with T2 mapping series.

I am very pleased to collaborate with Olea Medical® because Olea Medical® is helping us very much. From our clinical point of view, we have a very good correlation with the imaging and these biochemical properties using Olea Sphere®, the system developed with Olea Medical®. It is a very good tool to integrate both the morphological and the biochemical aspects and we are very happy with it.

Interview by Sophie Campana Tremblay

# OLEACEPTION



**Fayçal Djeridane**  
CEO, Olea Medical®

**Olea Imagein:** Could you please describe the concept hidden behind OleaCeption?

**Fayçal Djeridane:** Inspired by the famous movie of the same name, my vision of the “inception” is a dream phase, a kind of dream state where you consciously discover that you are dreaming and decide to take over. It can be called “lucid dreaming”.

“OleaCeption” stands for Olea dream, as mentioned in our tagline “Improved diagnosis for life™”. This is the mission we have set for ourselves. In the movie, an “inception” is the act of instilling an idea into someone’s mind by entering his or her dreams.

We consider that this is our responsibility to bring better patient care through improved technologies and we would like to spread this idea.

At their early stages, CT scans were really complicated to perform; now, it is like pushing a button and getting the results, it is simple. From its beginnings, CT technology has vastly improved – in speed, slice count, image quality. Scanners now produce images much faster and with higher resolution, allowing doctors to diagnose patients more accurately and to perform medical procedures with greater precision. MRI scanners are at the same stage as CT scanners were 30 years ago: they are big, complicated, noisy and stressful. In the future, I imagine them smaller, easier to use, noiseless, real time, quantitative, as the CT scans have become. I dream of similar improvements in MRI. I think the future is an evolution towards interventional.

“OleaCeption” is the ultimate Olea dream: designing a machine allowing to both diagnose and treat diseases.

**O.I:** What are the different key milestones to be hit in order to reach the OleaCeption objectives?

**F.D:** The first keystone is to reach standardization. When you are reading an article in Radiology 2010 from Kudo et al. [1] revealing that 5 different scanners performed on the same patient lead to 5 different diagnoses, you have no choice but to do something to improve it. As long as standardization does not exist, you cannot deal with machine learning, deep learning, big data, artificial intelligence, etc. Standardization is needed to draw meaningful conclusions. We are working in that direction, for diffusion, perfusion, etc. Our aim is to standardize all MR exams. That will be the first step.



The second step, and we really believe in it, is imaging genomics. This emerging field consists in rapidly identifying genes that influence the brain, cognition and risk for disease. We are working with Dr. Josep Puig, Prof. Salvador Pedraza and Dr. Gerard Blasco from IDIBGI (Girona, Spain) on Aging Imagenomics project to create imaging biomarkers that can identify the genomics of a disease, especially cancer, without biopsy. However, standardization is needed upstream.

Another interesting project is called “Gadgetron” and was presented at ISMRM; it is an open source framework for medical image reconstruction. This framework supports the vendor-independent ISMRM Raw Data (ISMRMRD) format and it is possible to convert from vendor-specific raw data formats – IDEA (Siemens®), EPIC (GE®), PARADISE (Philips®) or NSDE (Toshiba®) – to ISMRMRD format. Let’s have a look at the MRI images process: the export is already standardized with DICOM format; Olea Medical® aims to standardize the post-processing; Gadgetron, the reconstruction into k-space – and I am really interested in that; so, what about the images acquisition? The scientific community has already taken that direction. Standardization process has begun. The key is turned. We are on the move! Olea Medical® started and doctors who also noticed this need are working hard to achieve this goal. In order to obtain comparable images, the generation, reconstruction and post-processing of the images have to be standardized – homogeneous sequences and algorithms. Then, the results will be equivalent whatever the machine used to create the images.

Another important point, in addition to standardizing sequences and algorithms, is knowledge and expertise sharing. Olea Medical® provides a solution called “Olea Infinite®”, which is a software development kit (SDK), a universal platform to help standardize coding and post-processing applications development using boxes - one code for one box. Then, it is like playing Lego™ construction to build a clinical application. The advantages are that it is easy to handle, usable everywhere and language agnostic, allowing a sustainable development and standardized research. We are hence creating an Olea Exchange® community to share and spread knowledge between users, to find the best ideas where they are. The concept is totally vendor agnostic; the point is to pool the best ideas, to share with no border, all around the world, using a unique platform.

Teaching is also one of the key milestones. In order to develop this activity, we will offer the Olea Chair® Education to record the learning process. What is the Olea Chair® Education? It consists in sitting an imaging expert in a chair, using cameras looking at his/her hands and eyes, and then following his/her diagnostic process. Understanding how the expert makes his or her conclusions makes it possible to later teach the method to young radiologists. That is the idea. Moreover, if this can be transmitted to a junior radiologist, why couldn’t this also work towards a machine?

The aim is, of course, not to replace the human expert doctors. I am convinced that this is impossible: autopilots in planes exist for years but real pilots are still there.



Spontaneity is not something we expect when we consider a machine; if it were, we would probably be afraid of this. What we really want is to develop better tools to help people to give the best of themselves.

“OleaCepcion” in five words: detect, focus, characterize, treat, control (Figure 1). The patient lies in the scanner and whole-body pre-scans are done to detect any abnormality using whole-body diffusion or perfusion for example. Next, the machine starts zooming on the brain, the prostate, the liver, etc. depending on the information gathered from the pre-scans. The process will be coupled with blood examination, genomics and with every piece of information that is available in the patient’s health record. All these elements will be merged, connected to imaging in order to help providing a diagnosis. The key message here is to save analyzing time in order to spend more time with the patient and focus on the difficult tasks where the radiologist is definitely of significant value. And at the end, if necessary, treat the patient and monitor the system.

#### O.I: Which kind of pathologies will be cured by OleaCepcion?

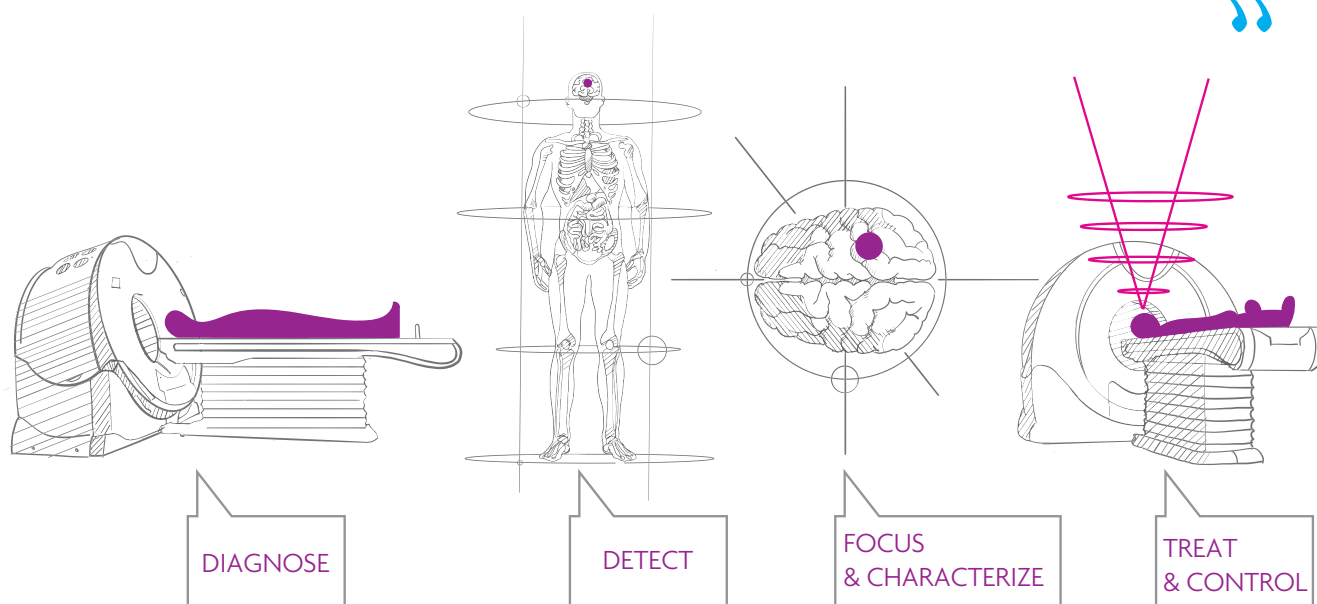
**F.D:** The aim is to treat all the pathologies that can be detected through imaging. There is no specific target. This idea is to first start with cancers using advanced technologies such as MR thermometry, or HIFU (High-Intensity Focused Ultrasound). HIFU energy allows the non-invasive destruction of target tissues by locally increasing the temperature, the location and heat being controlled using MRI in order to avoid any damages in the surrounding tissues. MR thermometry provides high temporal and spatial resolution to precisely monitor the temperature distribution within the targeted tissue to make sure the ultrasound system is properly calibrated and focused; it can also be used to assess the treatment immediately, and evaluate if the treatment needs to be extended. But there are plenty of other technologies.

I would love that, one day, people say: “do you remember that this crazy man said so 20 years ago?” (laugh).

“

“OleaCepcion” in five words: detect, focus, characterize, treat, control

”



**Figure 1:** OleaCepcion process.

**O.I:** How do you think the scientific and medical community will react when facing this revolutionary model? Which message would you like to address them?

**F.D:** What I would like to say is that unity is strength. Big data, machine learning, artificial intelligence, etc. are really promising technologies, however there is still a further stage to go through. As mentioned previously, all these concepts need standardization before becoming really useful. Big data without standardization is too early; as for machine learning, its efficiency will depend on the database used to teach the machines, resulting in a good “student” or a bad one. We should never forget that from artificial intelligence to artificial absurdity, there is only one step! Let’s look back 40 or 50 years ago, when the standardization of blood examinations was achieved. At that time, the blood glucose was depending on the method used to determine it. The standardization was needed in order to launch studies to find the blood glucose of diabetics for

example. Therefore, Olea Medical® thinks that the revolution is based on standardization first. When we are designing our tools, we keep in mind that it could be used for our parents, our children, our friends, our loved ones. When we are thinking this way, we are thinking completely differently, not in terms of sales or profit, but in terms of improved technologies to bring the best possible patient care. Using an analogy from the movie, I would like to be an “extractor” to plant this idea in everyone’s subconscious. This will be my “inception”.

1. Kudo K, Sasaki M, Yamada K, Momoshima S, Utsunomiya H, Shirato H, Ogasawara K. Differences in CT perfusion maps generated by different commercial software: quantitative analysis by using identical source data of acute stroke patients. *Radiology*. 2010 Jan;254(1):200-9.

Interview by Brianna Bucciarelli

Olea Care is Olea Medical®'s commitment to invest in research, innovations and social activism

**Olea Care**

GLOBAL HEALTH. GLOBAL ACTIONS. ONE GOAL.

# OleaImagein DIGEST: Intravoxel Incoherent Motion (IVIM)

➤ Intravoxel incoherent motion (IVIM) imaging can assess the microscopic translational displacements that occur in biological tissues, essentially due to molecular water diffusion (Brownian motion) and microcirculation of blood in the capillary network. Initially used in the brain, applications of IVIM tend to extend to other organs: liver, heart, prostate, rectum, etc. Here is a collection of selected papers on the topic.

➤ For more information on IVIM, please refer to Olea Imagein, Issue#2.

Investigators from Departments of Radiology at CHU Montpellier, France, and from Memorial Sloan Kettering Cancer Center, New York, USA, demonstrated the potential value of using IVIM in **rectal cancer: D parameter could allow an accurate evaluation of response after chemotherapy and radiation therapy (CRT) [1]**.

This retrospective study was conducted on 31 patients with rectal adenocarcinoma and pre- and post- CRT MRI examinations. ADC and IVIM (D, D\*, f) parameters were computed using 36 b-values. ADC and IVIM histogram metrics and median values were obtained, before and after CRT, and compared with histopathologic findings.

Median D and ADC values derived from either whole-volume or single-section analysis were useful for the assessment of tumor response to CRT: both values increased significantly after CRT and were significantly higher in good versus poor responders. In addition, histogram analysis did not yield better results than median values and may not be necessary in routine clinical practice. Finally, whole-tumor volume was preferred over single-section ROI analysis because of its superior inter-observer agreement and its potential to better capture the intra-tumoral heterogeneity.

1. Nougaret S, Vargas HA, Lakhman Y, Sudre R, Do RK, Bibeau F, Azria D, Assenat E, Molinari N, Pierredon MA, Rouanet P, Guiu B. Intravoxel Incoherent Motion-derived Histogram Metrics for Assessment of Response after Combined Chemotherapy and Radiation Therapy in Rectal Cancer: Initial Experience and Comparison between Single-Section and Volumetric Analyses. *Radiology*. 2016 Aug;280(2):446-54.

Department of Health Sciences, Diagnostic and Interventional Radiology at San Paolo Hospital, University of Milan and Department of Radiology at Insubria University, Varese, Italy, showed that **adding IVIM to the prostate protocol could increase the diagnostic performance to detect clinically relevant prostate cancer (PCa) [2]**.

This study was conducted on 31 patients with suspected prostate cancer (PCa), who underwent MRI with a protocol including T2-weighted imaging (T2WI), diffusion-weighted imaging (DWI) and dynamic contrast-enhanced (DCE) acquisitions. ADC map was computed using 3 b-values and a mono-exponential model; IVIM maps (D, D\*, f) were obtained using 10 b-values and a bi-exponential model.

The authors found that the specificity, sensitivity and accuracy of T2WI associated with DWI and IVIM were higher than for T2WI/DWI or IVIM alone. D and f were significantly lower in PCa than in noncancerous prostate parenchyma, and D\* was significantly higher in PCa compared to the healthy peripheral zone (PZ). ADC values have been found to have a rule to discriminate PCa reliably from normal areas and differed significantly in low- and intermediate-/high-grade PCa. IVIM parameters demonstrated an excellent performance for PZ PCa detection but were unable to distinguish between the different Gleason Score (GS). In the future, IVIM could be an appropriate alternative to DCE MRI.

➤ **Additional resource:** Cornud F, Pierre T, Legmann P. DWI of the prostate: should we use quantitative metrics to better characterize focal lesions originating in the peripheral zone? *Olea Imagein*, issue#2, p.32.

2. Pesapane F, Patella F, Fumarola EM, Panella S, Ierardi AM, Pompili GG, Franceschelli G, Angileri SA, Magenta Biasina A, Carrafiello G. Intravoxel Incoherent Motion (IVIM) Diffusion Weighted Imaging (DWI) in the Periferic Prostate Cancer Detection and Stratification. *Med Oncol*. 2017 Mar;34(3):35.

Investigators from Department of Radiology, Orbitopalpebral Surgery and Clinical Research Unit, Fondation Ophtalmologique Adolphe de Rothschild, Paris, from University Paris Descartes Sorbonne, INSERM UMR-S970, Cardiovascular Research Center, from APHP, European Hospital Georges Pompidou, Radiology Department, Paris, France, evaluated the repeatability of IVIM parameters in **orbital tumors: D parameter was robust, but f and D\* showed poorer test-retest repeatability [3]**.

Twenty-two patients with an orbital mass were included in this prospective study, in order to evaluate the intra- and inter-observer repeatability of IVIM parameters. Diffusion sequences were acquired twice about 17 minutes apart with 15 b-values. ADC and IVIM maps were computed using the Bayesian-based algorithm. Mean ADC, D, D\* and f values inside the orbit lesions were calculated.

In the orbital mass, test-retest repeatability was good for ADC and D and poor for f and D\*, while inter-observer repeatability was almost perfect for all IVIM parameters.

3. Lecler A, Savatovsky J, Balvay D, Zmuda M, Sadik JC, Galatoire O, Charbonneau F, Bergès O, Picard H, Fournier L. Repeatability of apparent diffusion coefficient and intravoxel incoherent motion parameters at 3.0 Tesla in orbital lesions. *Eur Radiol*. 2017; doi:10.1007/s00330-017-4933-6.





Investigators from Department of Radiology at CHU Cochin, University René Descartes, Paris, France, reported the interest of IVIM in **cardiac** imaging: **IVIM could be useful in the diagnosis and clinical relevance of micro-circulation disorders in progressive scleroderma [4].**

This prospective study was conducted on 17 patients with scleroderma and 10 control patients addressed for suspected cardiac tumor or arrhythmogenic right ventricular dysplasia. Cardiac MRI protocol included diffusion acquisition synchronized with breathing and T1 mapping in addition to conventional cine and late enhancement sequences. IVIM maps (D, D\*, f) were computed using 8 b-values.

The authors showed that IVIM was feasible in clinical practice and useful to diagnose the microcirculatory vascular insufficiency associated with scleroderma. A correlation with microscopic fibrosis was found on T1 mapping. IVIM could be interesting in screening sub-clinical heart disorders from scleroderma and could be used in other pathologies with microcirculatory issues due to interstitial myocardial fibrosis, such as diabetes or high blood pressure.

**Additional resource:**  
Croisille P, Boutelier T, Moulin K, Viallon M. IVIM in the Human Heart: a promising approach.  
Olea Imagein, Issue#2, p.52.

4. Gouya H, Lataud M, Safar K, Ben Arfi M, Terrier B, Mouthon L, Legmann P, Vignaux O. IRM cardiaque dans la sclérodémie: Apport de la diffusion IVIM pour le diagnostic de l'atteinte microcirculatoire corrélée au mapping T1. JFR 2014 (Paris, France)



Investigators from Department of Radiology at AZ St. Jan Brugge-Oostende AV, Bruges, Belgium, from Institute for Healthcare Policy, University of Leuven, Belgium, and from Olea Medical®, France, found that IVIM could be helpful in characterizing **liver** lesions: **D parameter can differentiate hepatocellular adenomas (HCAs) from focal nodular hyperplasias (FNHs) [5].**

In this prospective study, 21 patients with focal liver lesions (8 HCAs and 13 FNHs) underwent MRI with both respiratory-triggered IVIM and dynamic contrast-enhanced (DCE) acquisitions. ADC and IVIM maps were computed using 4 b-values, perfusion maps were obtained using the Extended Tofts model.

Unlike ADC, Ve and time-intensity curves, IVIM D parameter and DCE Ktrans parameter were both able to differentiate HCAs from FNHs: their values were significantly lower in HCAs compared to FNHs. This study suggests that there is a true tissue diffusion difference between HCAs and FNHs, based on the histological nature of the lesions.

**Additional resource:**  
Wagner M. Diffusion-weighted imaging in the liver: role of IVIM approach.  
Olea Imagein, Issue#2, p.43.

5. Jerjir N, Bruyneel L, Haspeslagh M, Quenet S, Coenegrachts K. Intravoxel incoherent motion and dynamic contrast-enhanced MRI for differentiation between hepatocellular adenoma and focal nodular hyperplasia. Br J Radiol. 2017 Jun 7:20170007.



Investigators from Irmandade da Santa Casa de Misericórdia de São Paulo, Brasil, investigated IVIM on **intracranial neoplasms** and compared with DSC: **f parameter correlated with rCBV and had the best specificity to discriminate between low- and high-grade tumors [6].**

The double aim of this study, conducted on 25 patients, was a) to evaluate the feasibility of IVIM in differentiating the histologic grade of intracranial neoplasms, and b) to compare the perfusion measurement between IVIM and DSC. Besides conventional MR protocol, DSC and diffusion sequences (10 b-values) were acquired. ADC, IVIM (D, D\*, f) and perfusion (rCBV, rCBF, MTT) maps were computed.

Tumor ADC and D were found to be correlated and significantly higher in the low-grade than in the high-grade tumors. Conversely, f was lower in the low-grade tumors; it also had the best specificity (90%) to discriminate between the neoplasms, with a good sensitivity (80%). D\* showed no statistical differences between both groups, and had the lowest diagnosis efficacy. Finally, f showed a correlation with rCBV, confirming the findings of recent studies, and could be considered as an indicator for the evaluation of capillary density of tumors.

**Additional resource:**  
Catanese A, Casolino D, Malacario F, Zenesini C, Toni F, Cirillo L, Agati L. Intravoxel Incoherent Motion MR Imaging In The Brain Tumor: Technical Note.  
AINR/ESNR 2015 (Naples, Italy).

6. Cardoso Fragoso D, Lio da Mota Gonçalves Filho A, Torres Pacheco F, Hoffmann Nunes R, Foerster B, da Rocha AJ, Maia Junior ACM. a) Preoperative grading of intracranial neoplasms using intravoxel incoherent motion (IVIM) DWI. b) Can the contrast-free MR perfusion based on the intravoxel incoherent motion imaging (IVIM) substitute the dynamic susceptibility contrast-enhanced imaging (DSC-MR) in estimating capillary density? – Correlation between the two techniques. JPR 2016 (São Paulo, Brazil)

#### Additional resources:

- Casselman JW. IVIM for Head and Neck application. Olea Imagein, issue#2, p.50.
- Casselman JW. The potential of IVIM. Olea Imagein, issue#3, p.25.
- Espinoza-Boireau S. Functional Imaging in Head & Neck tumors. PhD Thesis, under the direction of Prof. Siauve. Paris Descartes University, Paris, France. 2016.

## Reminder:

IVIM model is described by the following equation:

$$S(b) = S_0 [fe^{-bD^*} + (1-f)e^{-bD}]$$

Where:

- S(b) is the signal;
- S<sub>0</sub> the reference signal;
- D the molecular diffusion restriction coefficient;
- D\* the tissue perfusion related coefficient;
- f the perfusion fraction.





# Meet Olea Medical® in 2018

## February 28-March 4

European Congress of Radiology (ECR)  
Vienna, Austria

## April 13-14

Workshop on prostate  
conducted by Dr. Cornud  
Paris, France



## June 2-7

American Society of Neuroradiology  
(ASNR)  
56th Annual Meeting  
Vancouver, Canada



## June 16-21

International Society for Magnetic Resonance  
in Medicine (ISMRM)  
26th Annual Meeting  
Paris, France

## October 12-15

Journées Françaises de Radiologie (JFR)  
Paris, France

## November 25-30

Radiological Society of North America (RSNA)  
Chicago, USA



# Word scramble

G	X	X	E	D	N	I	S	X	V	L	I	D	D	M
C	I	R	M	L	A	N	O	I	T	C	N	U	F	U
N	C	L	A	Y	S	Z	N	C	C	N	C	A	V	S
J	L	R	Y	T	T	R	S	M	O	Z	C	N	N	C
A	K	F	Q	T	E	T	X	I	X	P	J	O	W	U
F	X	U	T	A	M	X	S	Q	B	L	I	I	H	L
O	Z	C	R	U	F	U	T	G	L	T	S	T	G	O
O	N	S	S	T	F	M	L	U	U	X	Y	P	D	S
N	D	O	W	F	O	U	A	L	R	I	F	E	A	K
D	N	S	I	H	C	S	O	V	N	E	S	C	F	E
O	Z	D	V	O	U	V	I	B	Y	E	L	A	S	L
H	S	M	C	J	E	W	Y	S	O	B	X	E	V	E
H	Y	E	P	R	W	U	Z	A	L	K	F	L	T	T
C	S	S	M	W	H	T	M	I	K	L	J	O	V	A
T	Q	C	I	T	E	H	T	N	Y	S	C	C	Z	L

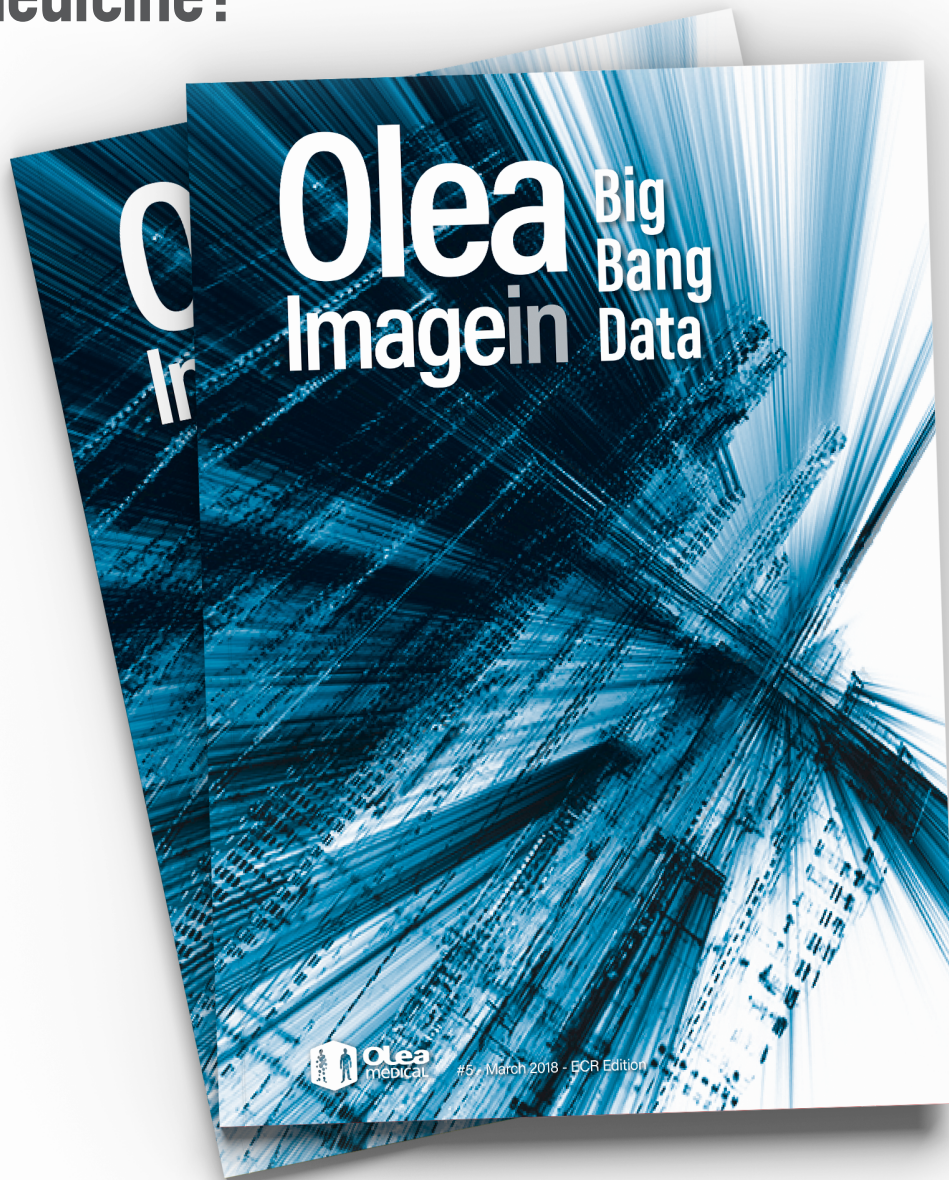- SINDEX
- KURTOSIS
- DIFFUSION
- GLUCOCEST
- FUNCTIONALMRI
- SYNTHETIC
- TEXTURE
- MUSCULOSKELETAL
- OLEACEPTION
- MREVOOLUTION



“Your proposal is innovative. Unfortunately, we won’t be able to use it because we’ve never tried something like this before.”

Coming  
next

Would you like to learn more about big data,  
machine learning and artificial intelligence  
in medicine?



Subscribe Online  
to Olea Imagein  
upcoming edition at  
[www.olea-medical.com](http://www.olea-medical.com)



April, 13-14 2018



# Hands-on Workshop on Prostate MRI

## Informations, registration and accreditation

[imagerieudri@gmail.com](mailto:imagerieudri@gmail.com)

Course fee: 490 €

Residents: 300 € (on presentation of a written document from the department).

This workshop is officially accredited by EACCME<sup>®</sup> for 9 European CME credits (ECMEC<sup>®</sup>).

**Organized by**  
**François Cornud, M.D.**  
*Hôpital Cochin,  
Department of Radiology  
(Paul Legmann,  
M.D., Ph.D.)*



UNIVERSITÉ  
**PARIS  
DESCARTES**