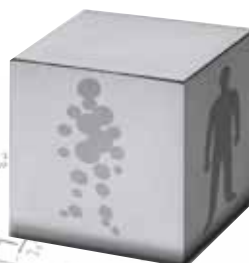

Case Report

**Recurrent Tumor
and Radiation Necrosis
in the Same Case**

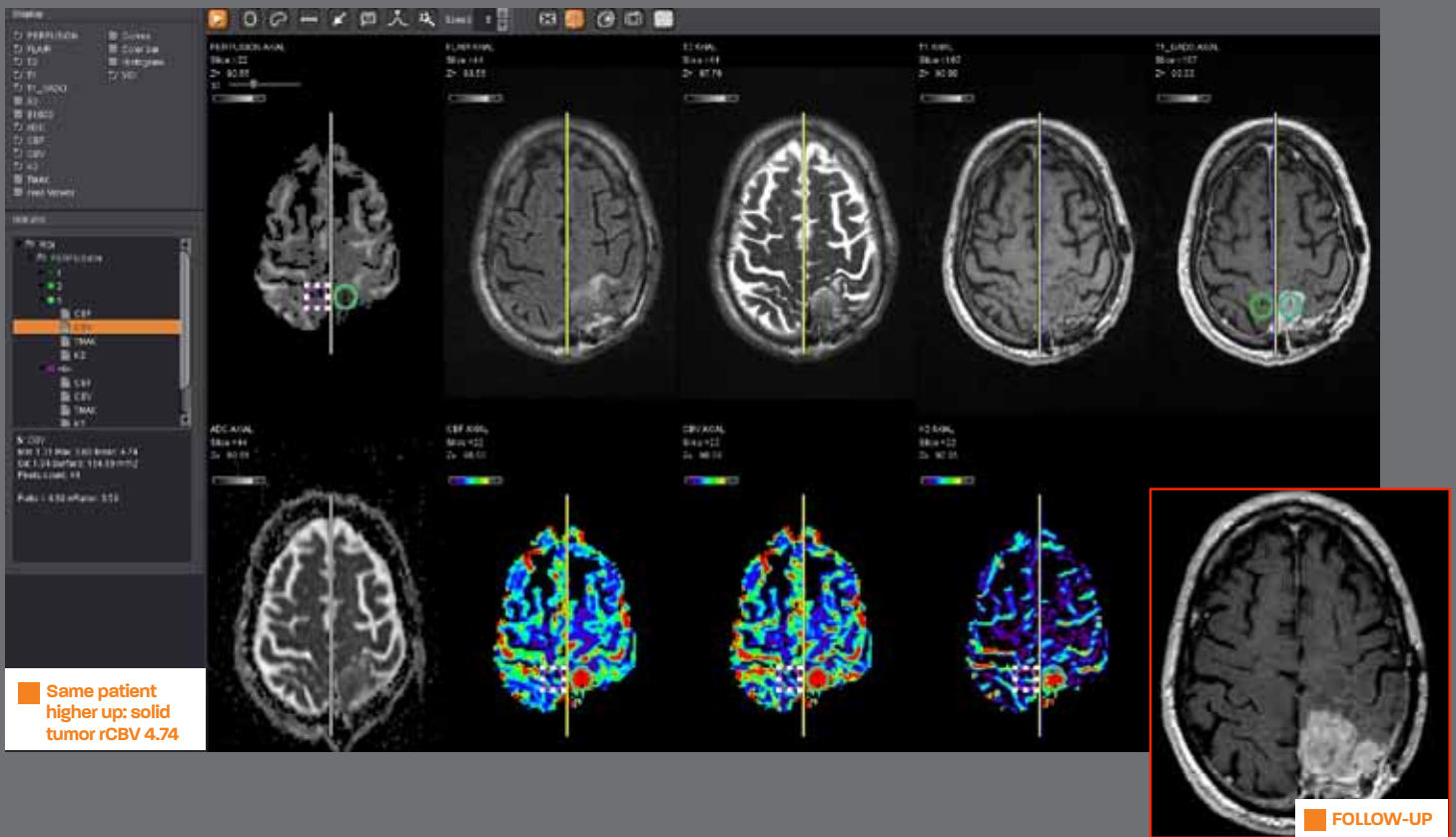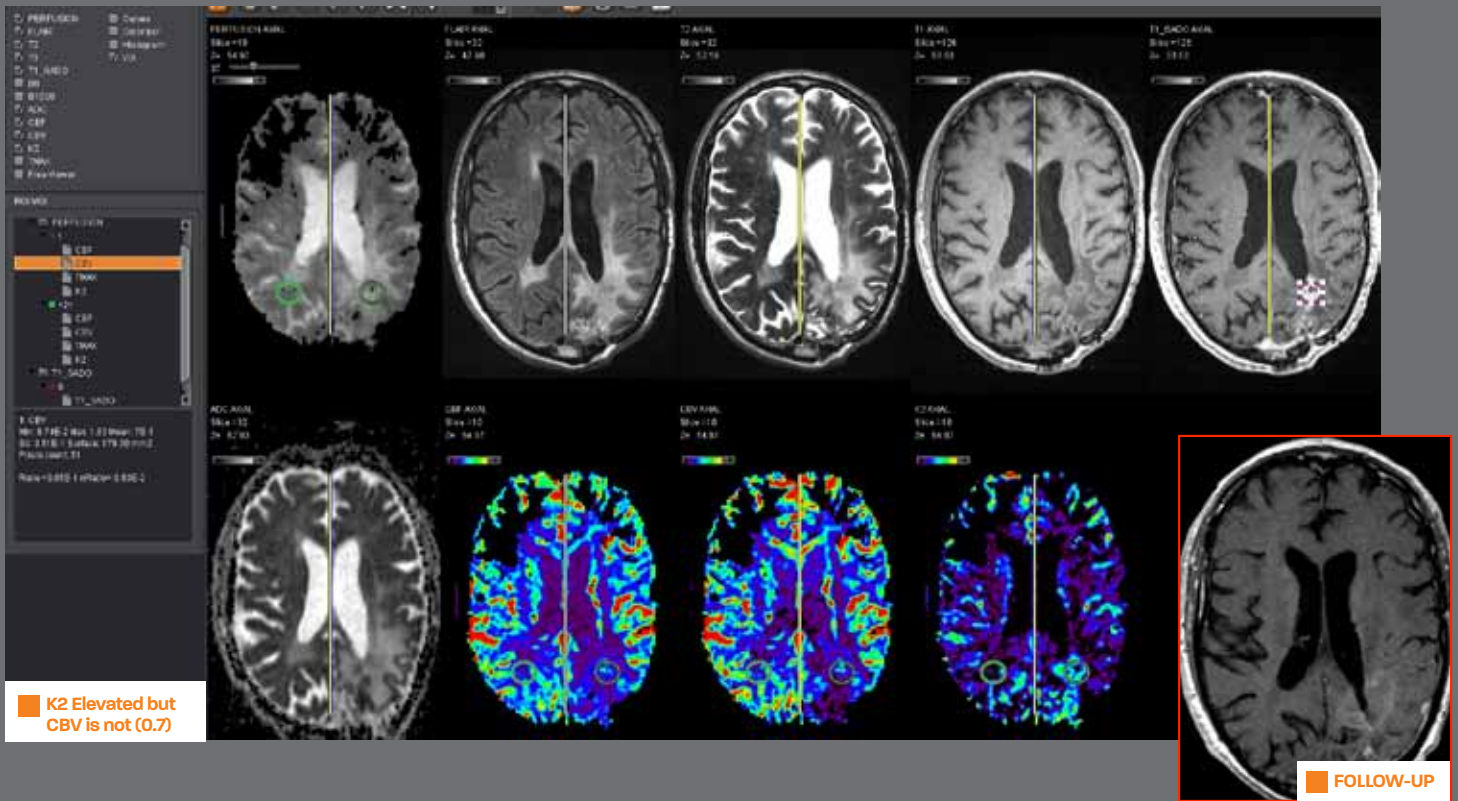
Metastasis



93, avenue des Sorbiers
13600 La Ciotat - FRANCE
TEL +33 (0)4 42 71 24 20
FAX +33 (0)4 42 71 24 27
contact@olea-medical.com

PATIENT HISTORY / RECURRENT TUMOR AND RADIATION NECROSIS IN THE SAME CASE

71 year-old man with glioblastoma



PATIENT HISTORY / METASTASIS

56 year-old man with rectal carcinoma: One of the brain lesions was resected: path : metastasis from rectal adenocarcinoma.

