


Case Report

**STROKE: Early Complete
MCA Recanalization**



93, avenue des Sorbiers
13600 La Ciotat - FRANCE
TEL +33 (0)4 42 71 24 20
FAX +33 (0)4 42 71 24 27
contact@olea-medical.com

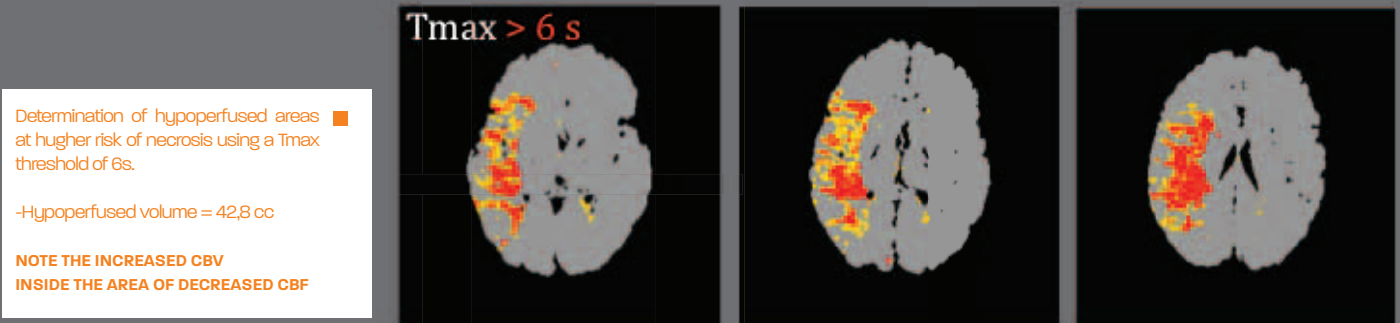
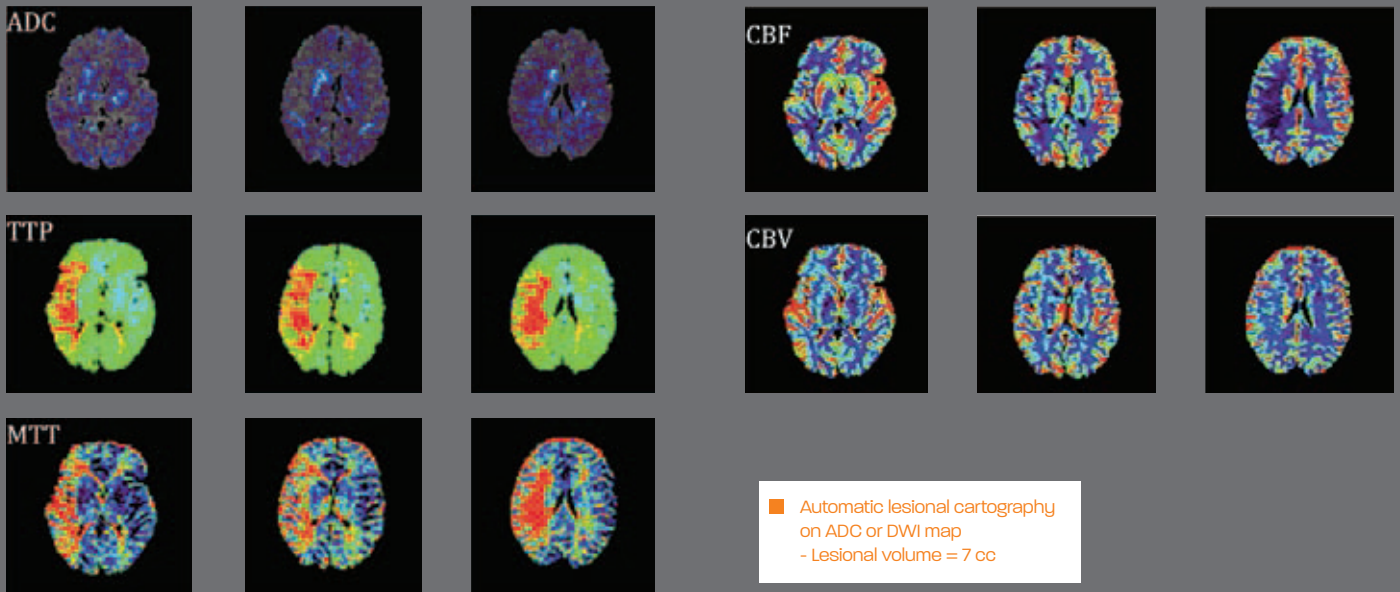
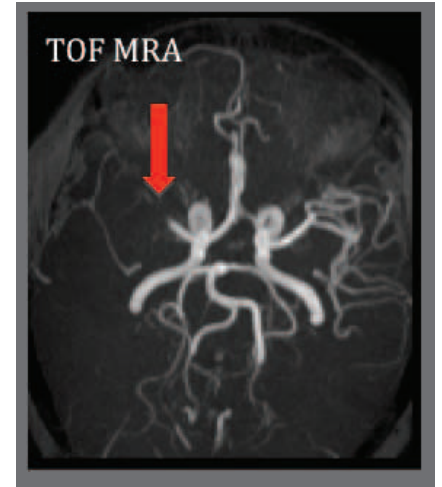
Patient history

A 45 year-old woman presented a sudden left hemiparesis with dysarthria. BP was 150 – 85 mmHg and medical history showed no vascular risk factor. Upon arrival, the NIHSS score was 6 and the ECG was normal.

An MRI was performed immediately upon arrival (90 minutes after stroke onset). Time-of-flight MR angiography showed a proximal middle cerebral artery (MCA) occlusion.

FLAIR images were normal while perfusion-weighted imaging showed a large area of decreased CBF area associated with a significant increase of CBV, MTT and Tmax values.

The automatic lesion cartography on ADC and DWI map with PerfScape and NeuroScape (Olea Medical, La Ciotat, France) showed a lesional volume of 7 cc. Analysis of hypoperfused area at higher risk of necrosis using a Tmax threshold of 6s showed a hypoperfused volume of 42.8 cc.



IV thrombolysis (IVT) was performed just after MRI, followed by full neurological recovery less than one hour after. Transcranial Doppler performed during IVT revealed an early and complete MCA reca-

nalization confirmed by a CT angiogram performed 24 hours later. Antiplatelet therapy was administered 24h after IVT. No complication was observed.