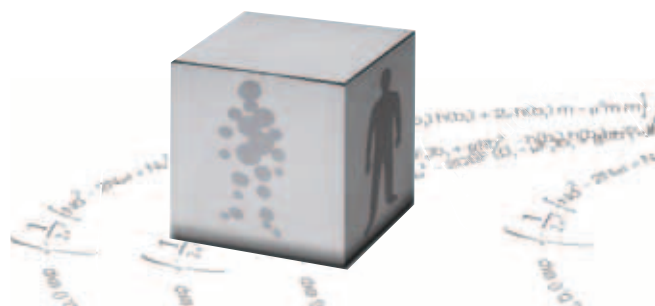


Case Report

**STROKE: Fronto-insular
MCA occlusion**



93, avenue des Sorbiers
13600 La Ciotat - FRANCE
TEL + 33 (0)4 42 71 24 20
FAX +33 (0)4 42 71 24 27
contact@olea-medical.com

PATIENT HISTORY

A 73 year-old woman presented with acute onset left hemiparesis with confusion and fall. BP was 188 – 88 mmHg and medical history showed diabetes.

Upon arrival, GCS eye subscore was 3, GCS verbal subscore was 4 and GCS motor subscore was 4.; EEG was abnormal due to an underlying structural lesion in the right fronto-temporal region.

IMAGING FINDING

A CT was performed immediately upon arrival (67 minutes after stroke onset). CTA showed a right fronto-in-sular MCA branch occlusion.

Perfusion imaging showed a large area of reduced CBF associated with a significant increase of CBV and prolonged TMAX, MTT and TTP values. Permeability surface area product (PS) showed no area of increase. A significant increase of CBF at the anterior border of the infarction was noticed.

DISCUSSION

IV Tpa was given just after the CT, followed by severe right heachaches. Tpa was suspended and a 2nd CT was performed showing no signs of hemorrhage and Tpa was resumed. The elevated BP was treated by labetalol 5mg IV pushx2 and later labelatol gtt.

The patient 's lethargy improved and she gradually became alert and oriented. Her left arm was initially plegic, but improved during hospitalization to minimal movements of the left hand and fingers. She was able to get out of bed to use the bathroom. She was at last medically stable to be discharged to acute rehab.

