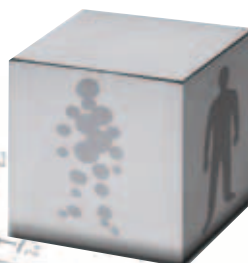


# Case Report

Recurrent tumor  
and radiation necrosis  
in the same case

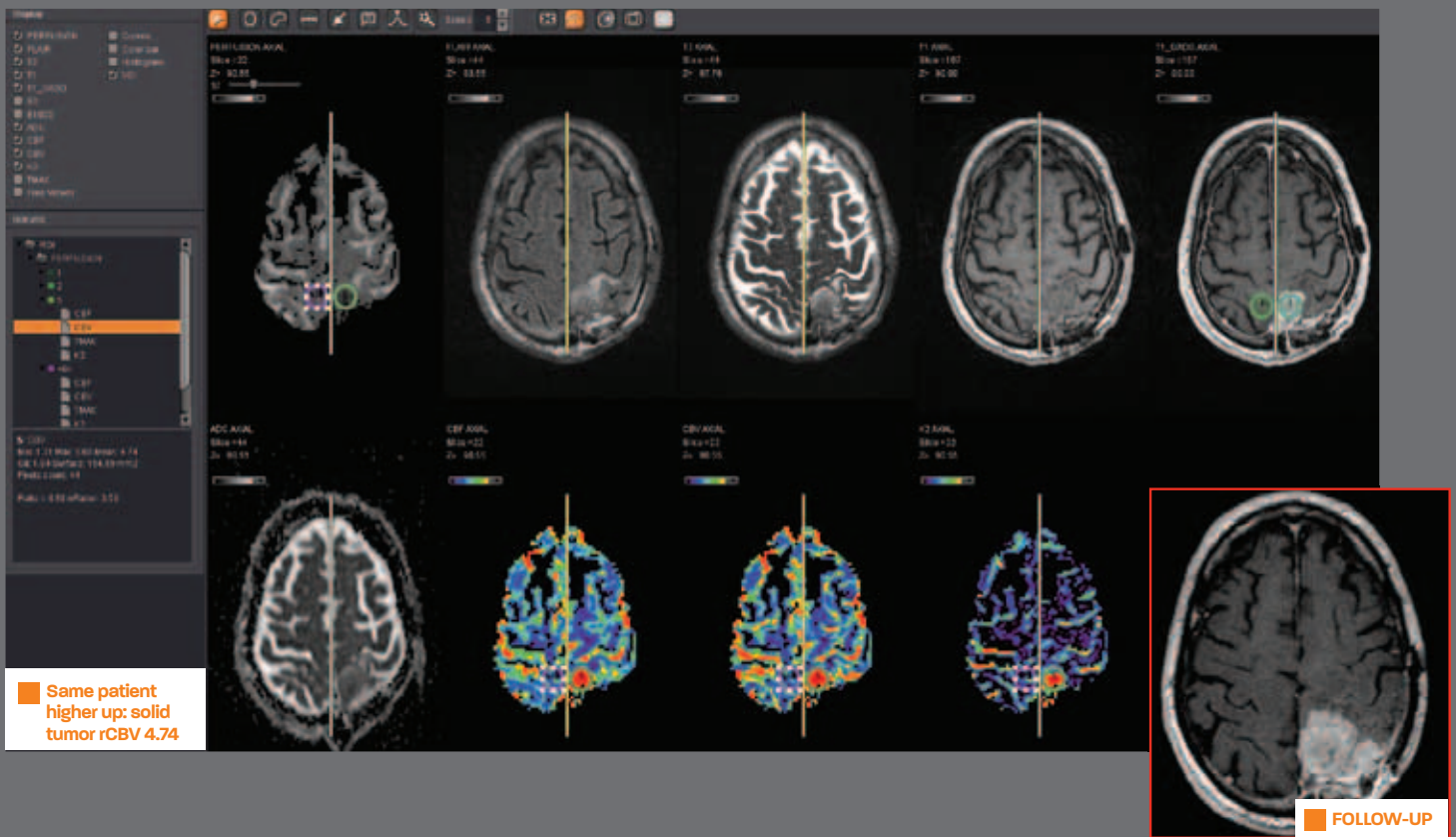
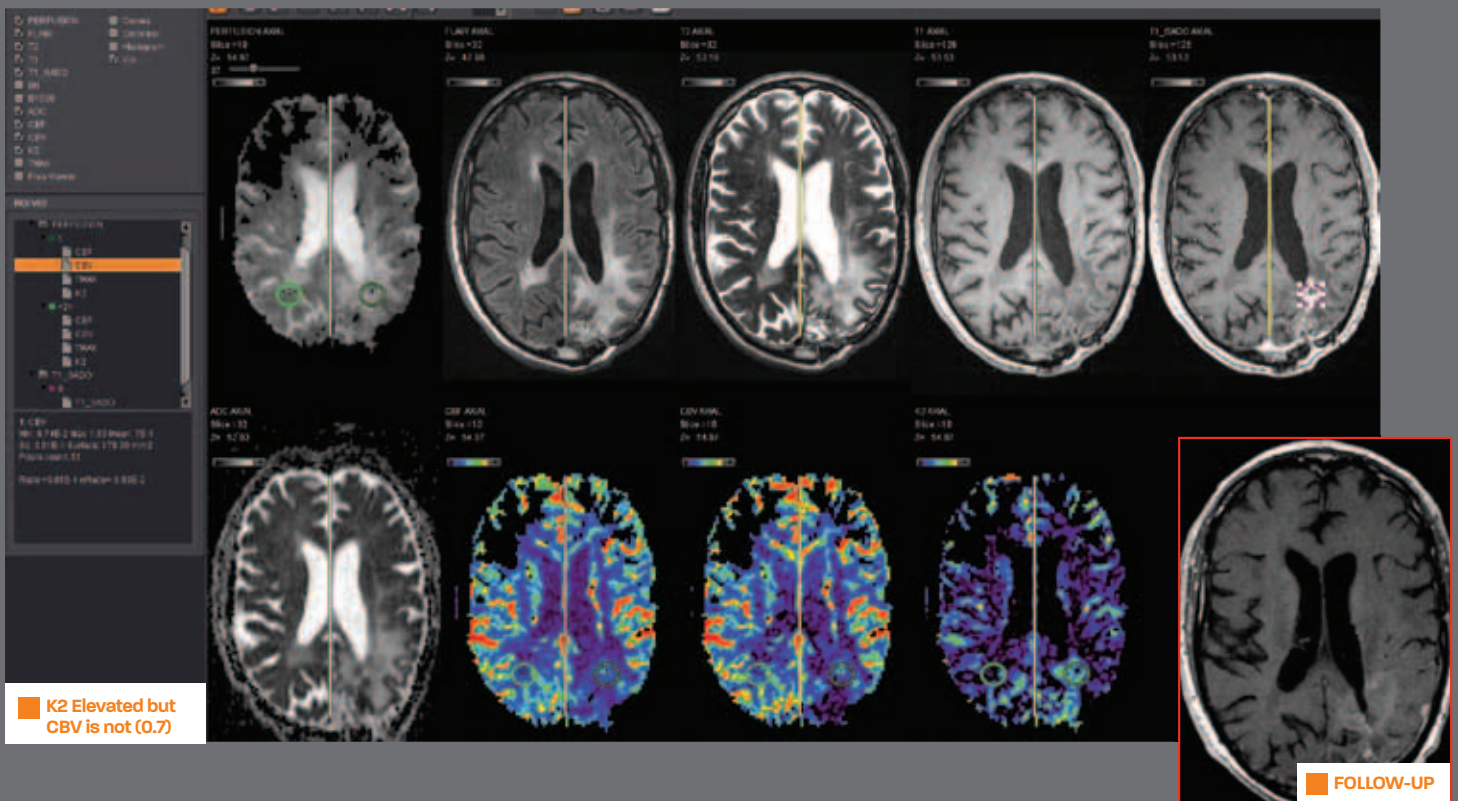
Metastasis



93, avenue des Sorbiers  
13600 La Ciotat - FRANCE  
TEL +33 (0)4 42 71 24 20  
FAX +33 (0)4 42 71 24 27  
contact@olea-medical.com

PATIENT HISTORY / RECURRENT TUMOR AND RADIATION NECROSIS IN THE SAME CASE

71 year-old man with glioblastoma



## PATIENT HISTORY / METASTASIS

56 year-old man with rectal carcinoma: One of the brain lesions was resected: path : metastasis from rectal adenocarcinoma.

