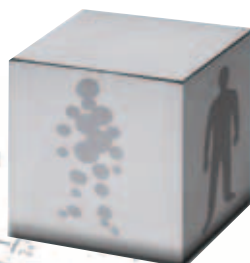

Case Report

Low-Grade Glioma



93, avenue des Sorbiers
13600 La Ciotat - FRANCE
TEL +33 (0)4 42 71 24 20
FAX +33 (0)4 42 71 24 27
contact@olea-medical.com

PATIENT HISTORY

A 51 year old woman with a history of LED and thyroid insufficiency, complained of continuous headache and chronic fatigue.

An MRI examination in an outside hospital was performed. She then was referred to a neuro-oncologist in our hospital.

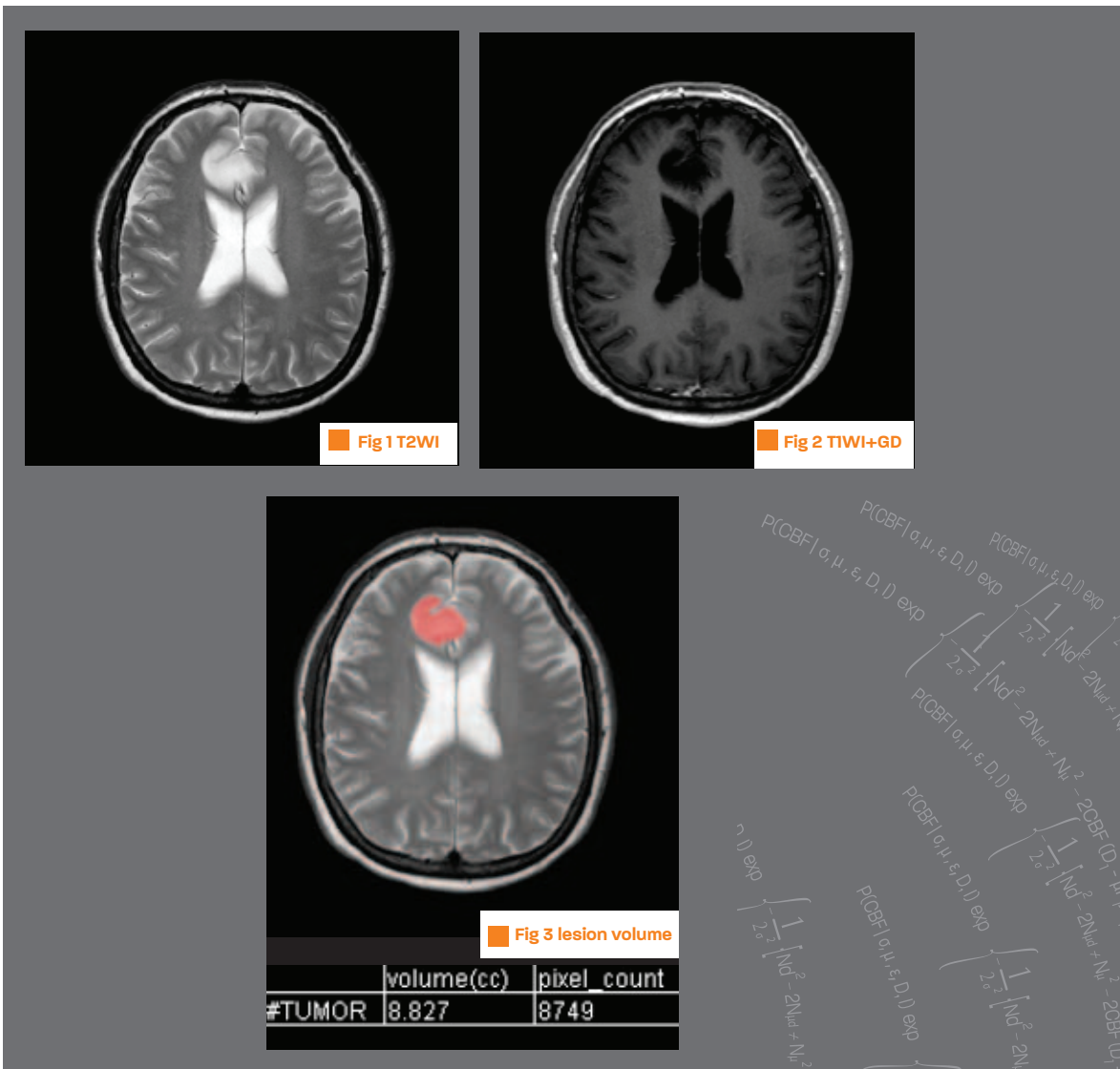
IMAGING FINDINGS

A right frontal parasagittal mass lesion was found, with hyposignal on T1, hypersignal on T2 and no contrast enhancement nor peri-lesional oedema (fig 1 and 2). The volume of the lesion, calculated with the Olea Medical software, was 8.83 cc.

(fig 3) There was no diffusion restriction (fig 5). No increased perfusion (fig 6).

MRS showed increased choline and reduced Naa with Cho/Naa 1.48. No clear ml.(fig 4).

A PET-FET scan showed no increased signal in the right frontal region (fig 7). The imaging findings were compatible with a low-grade glioma, WHO grade 2.



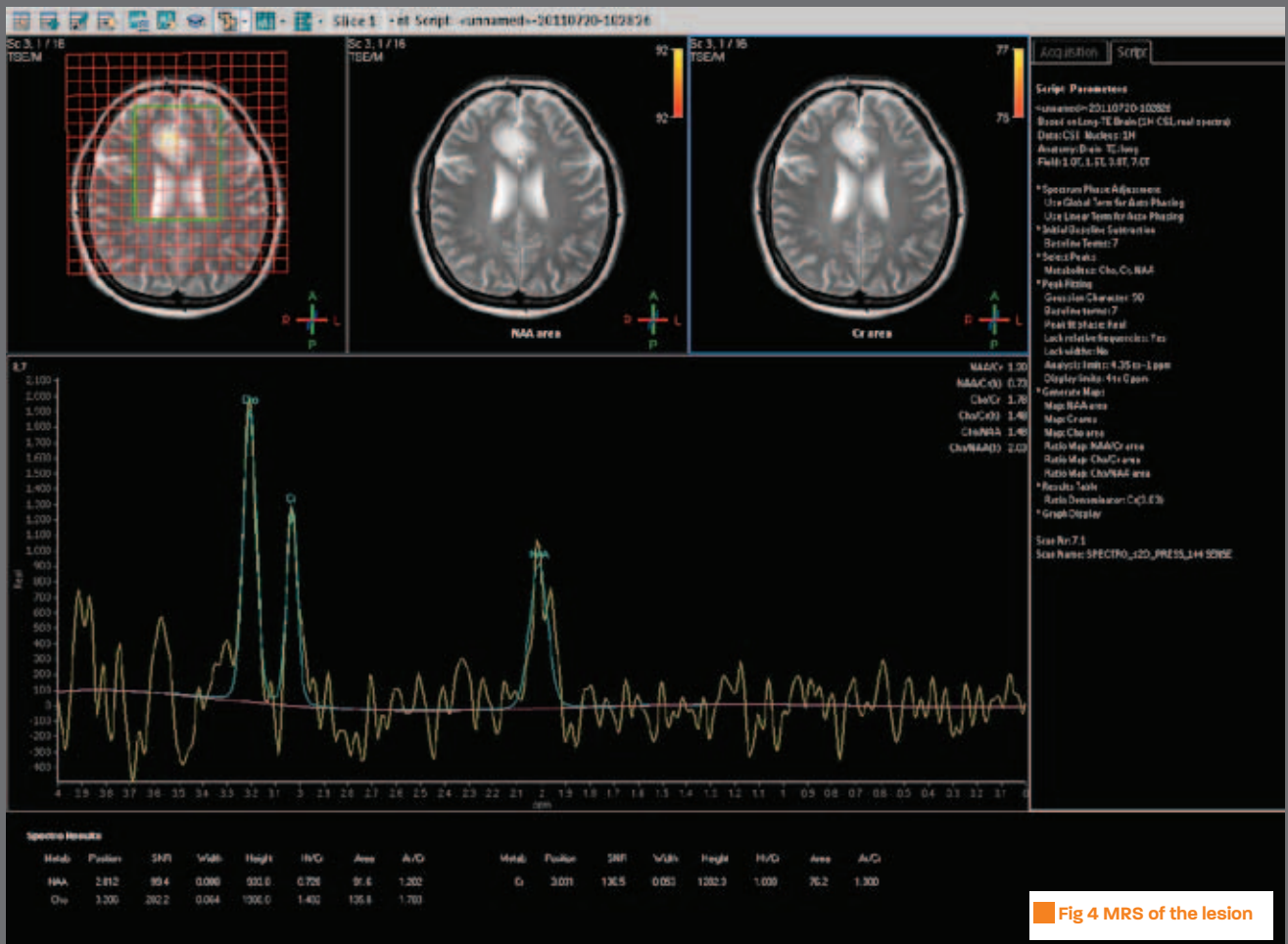
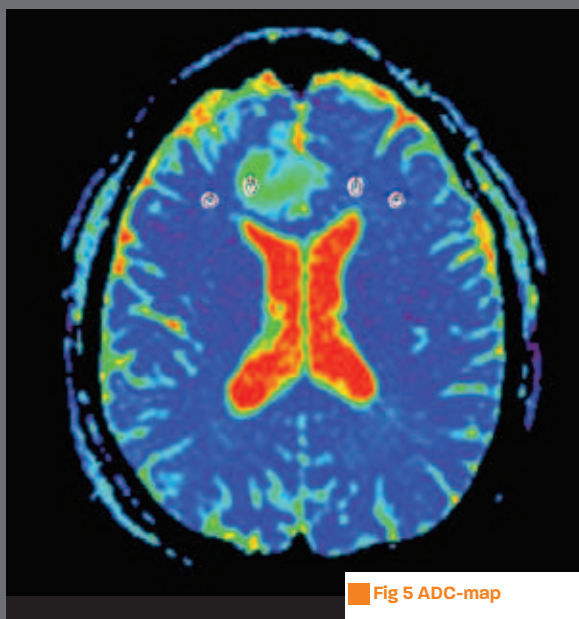
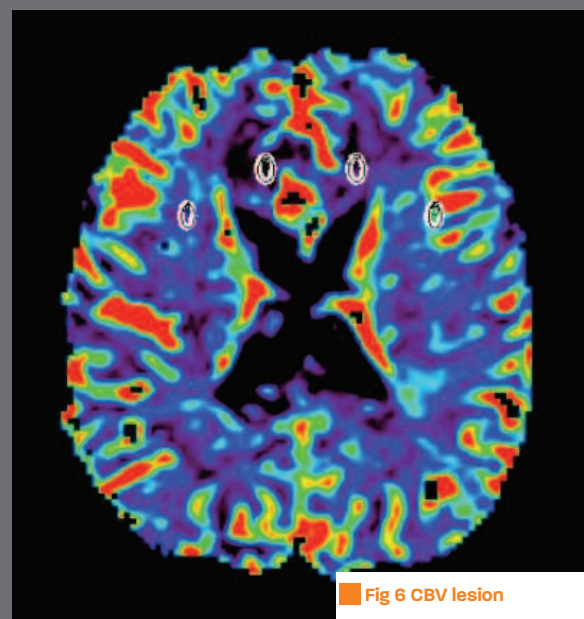


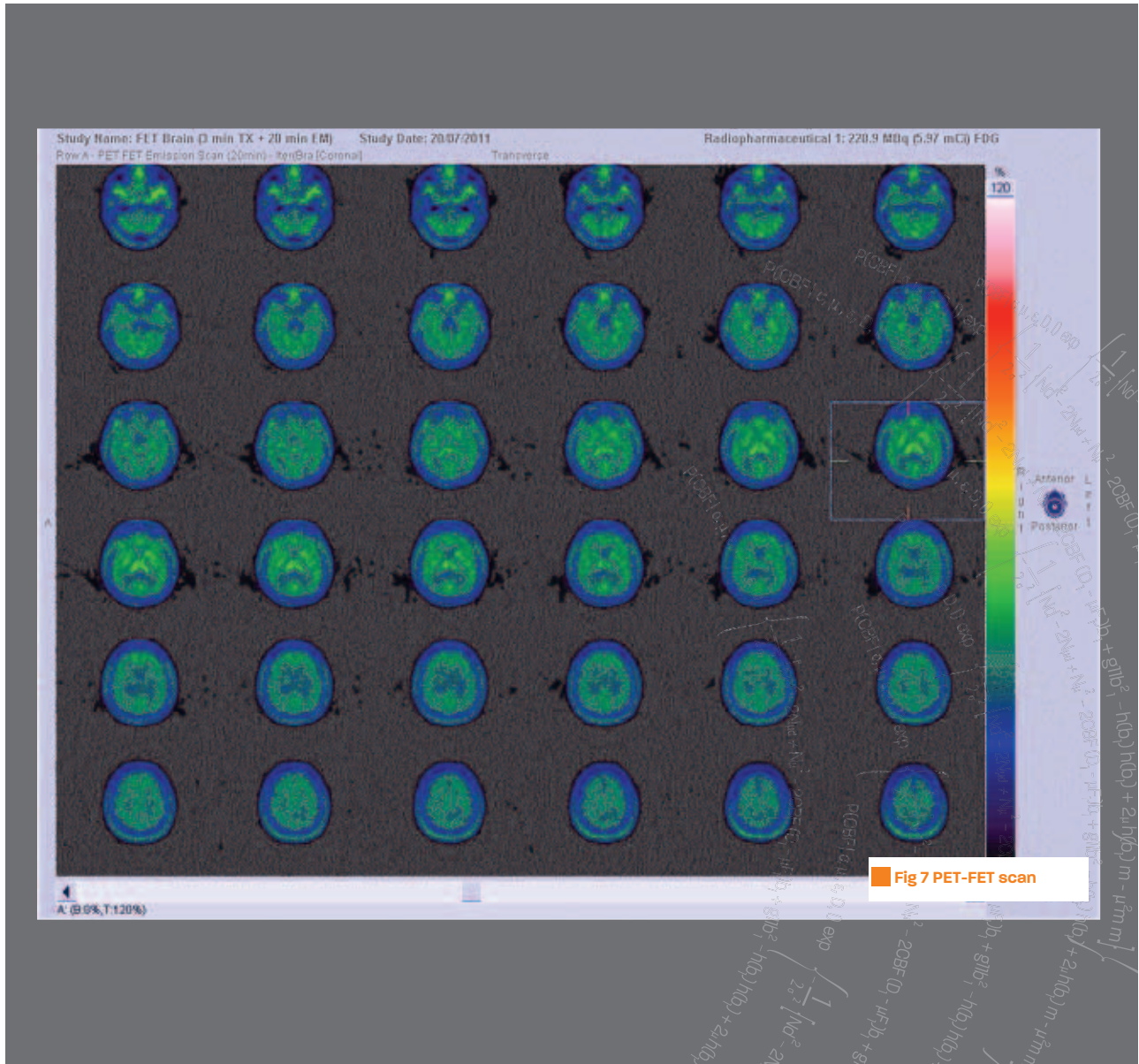
Fig 4 MRS of the lesion



ADC	<2>	0	1	3
ratio	0	2.39	1.09	1.01
ratioNorm	0	1.39	0.09	0.01
max	491.02	1272.02	519.01	514
mean	454.64	1088.62	495	458.87
min	433.99	1002.98	445	407
pixelCount	22	21	21	22
sd	14.14	78.67	20.22	34.84
surface	11.37 mm2	10.85 mm2	10.85 mm2	11.37 mm2



CBV	<7>	4	5	6
ratio	0	1.55	2.74	0.82
ratioNorm	0	0.55	1.74	-0.18
max	0.88	1.21	1.89	0.71
mean	0.64	1	1.77	0.53
min	0.51	0.83	1.63	0.37
pixelCount	8	6	6	8
sd	0.12	0.11	0.08	0.13
surface	24.5 mm2	18.38 mm2	18.38 mm2	24.5 mm2



DISCUSSION

This diagnosis was communicated to the patient and an advice for tumour resection was given (best option in the long run). The patient however preferred waiting and a follow-up with MRI is planned.